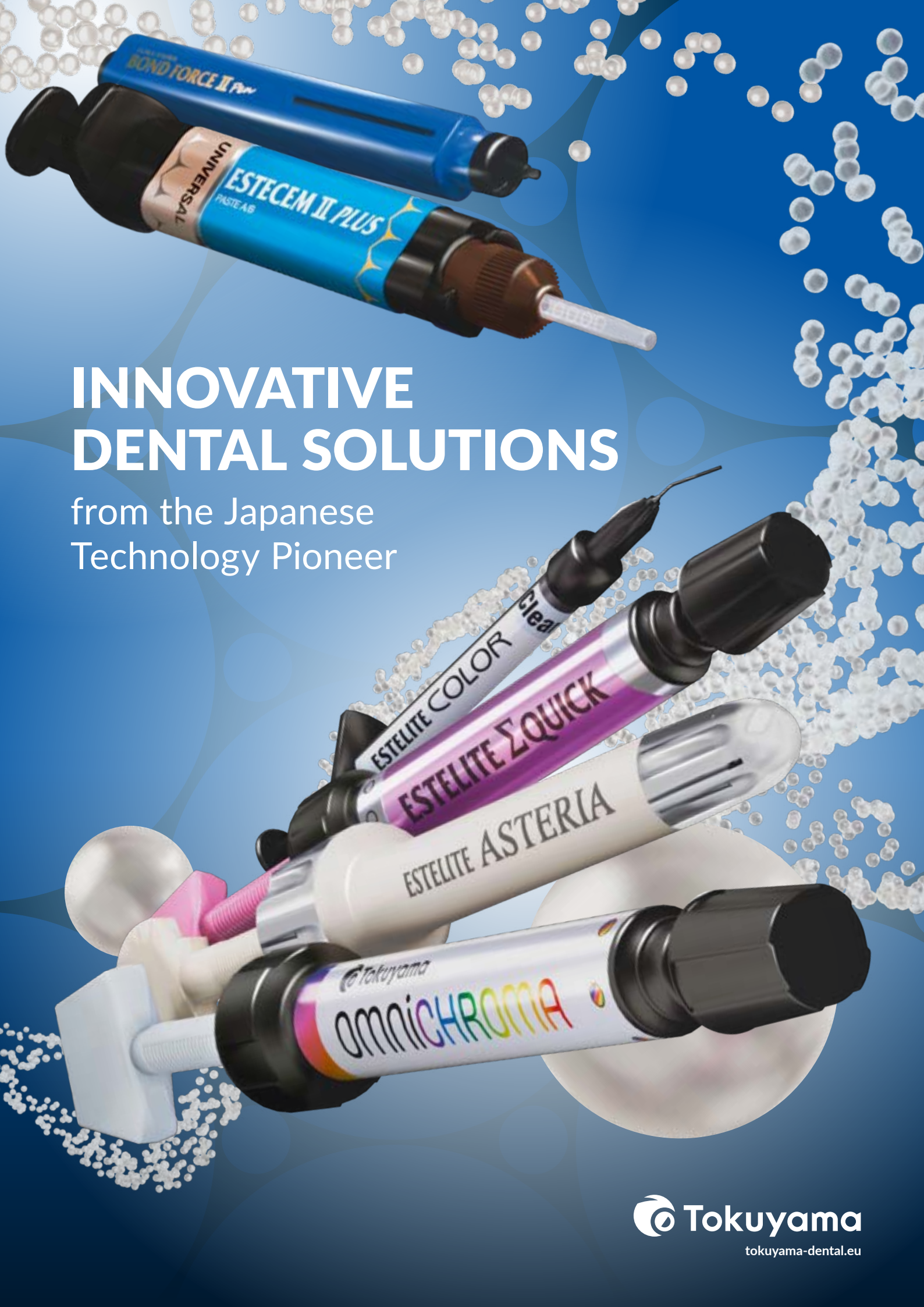


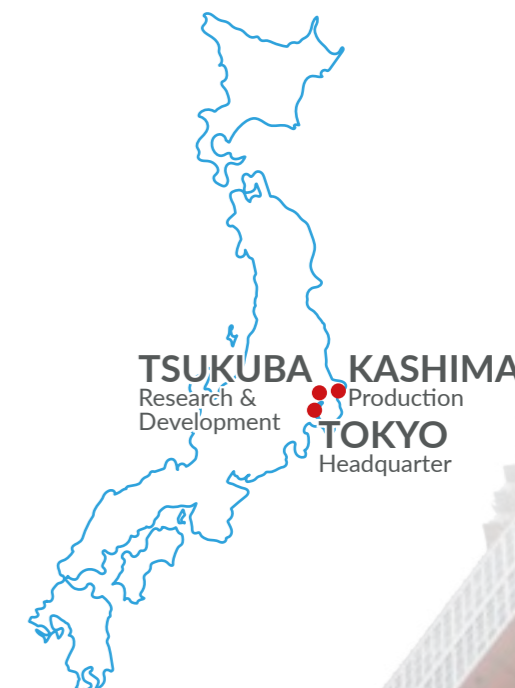
INNOVATIVE DENTAL SOLUTIONS

from the Japanese
Technology Pioneer

THE MOTHER

The TOKUYAMA DENTAL Corporation – a traditional Japanese company



1. Innovation

TOKUYAMA DENTAL is not looking to invent, we are looking to innovate. Innovation is the process of creating a product that provides a more efficient and faster way for you to achieve a desired result. TOKUYAMA DENTAL is dedicated to improve the lives of you and your patients'.

2. Product efficiency and replicable results

Tokuyama Dental products are submitted to rigorous testing that simulate intra-oral environments, prior to invo-testing. It is our number one priority that Tokuyama Dental products always perform at or above clinical expectations.

3. Quality

Tokuyama Dental is sure to take utmost care when manufacturing, packaging, storing, and shipping products, to ensure all attributes of our products perform to customer satisfaction.

4. Customer service and satisfaction

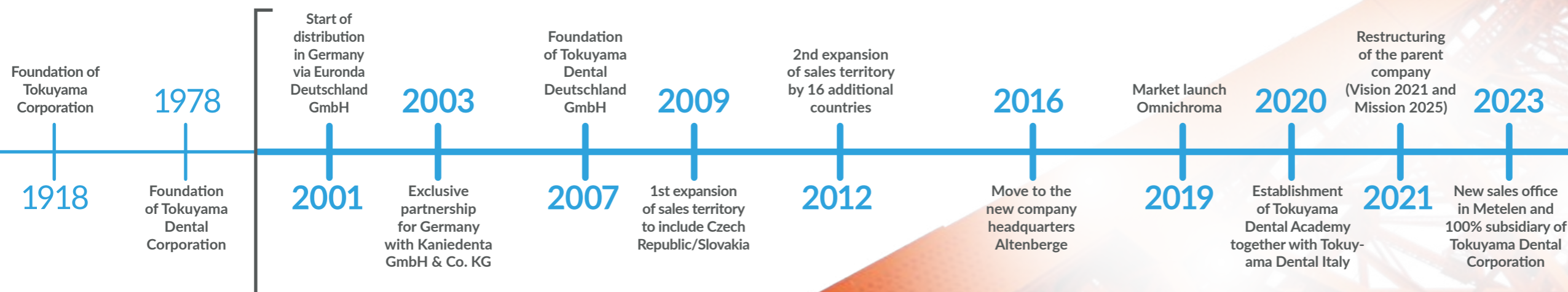
Tokuyama Dental treats our customers like family, and as such, we are determined to offer quick and easy solutions for our customers. Providing superior customer service is our primary mission.

5. Social responsibility

Tokuyama Dental is committed to Corporate Social Responsibility by contributing to economic development, while improving the quality of life of our workforce and their families, as well as the local community and society at large.

TOKUYAMA DENTAL draws on nearly a century of accomplishments and knowledge to gain a competitive advantage in today's dentistry. Operating on a global scale, our mission is to listen to your needs, incorporate your voice into the development of innovative products, and ensure our products meet the highest standards of quality. Tokuyama Dental is characterized by cutting-edge technology and developing specialty products that improve your daily life.

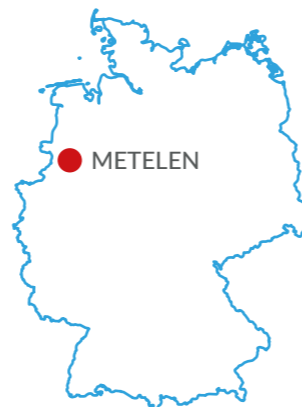TOKUYAMA DENTAL our constant pursuit of excellence and innovation thrives from a strong link between our company and visionary Dental Professionals, who shape the future of dentistry. TOKUYAMA DENTAL is 100% committed to Innovating Tomorrow's Dentistry, Today. Our spirit is embodied in five values which represent the vary essence of TOKUYAMA DENTAL and will always continue to do so.





THE DAUGHTER

TOKUYAMA DENTAL
Deutschland GmbH –
from Münster
to Northern Europe



TOKUYAMA DENTAL Germany is the subsidiary for the distribution of dental products in Germany, the Czech Republic, Slovakia, Hungary, Poland, Austria, Switzerland, Liechtenstein, Luxembourg, Belgium, The Netherlands, Ireland, Great Britain, Iceland, Norway, Denmark, Sweden, Finland, Estonia, Latvia and Lithuania.

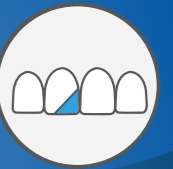The sales office of TOKUYAMA DENTAL Germany is located in Metelen – near Münster. From this location, dentists and dental dealers in Germany and the aforementioned European countries are supplied and supported with dental products.

A modern service concept supports dentists and dealers personally and competently in the use and distribution of dental materials in these areas.

6

Composite

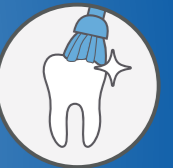Multiple award-winning filling materials



26

Polisher & Brushes

Rotating grinding and polishing instruments



30

Adhesives

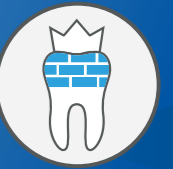Adhesion - State of the Art



38

Cement

Adhesive luting cements and posts



44

Impression Materials

Precise even under adverse conditions



48

Dentine Sealant

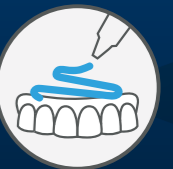For hypersensitive dentine



50

Relining Material

Hard and durable soft relining



COMPOSITE

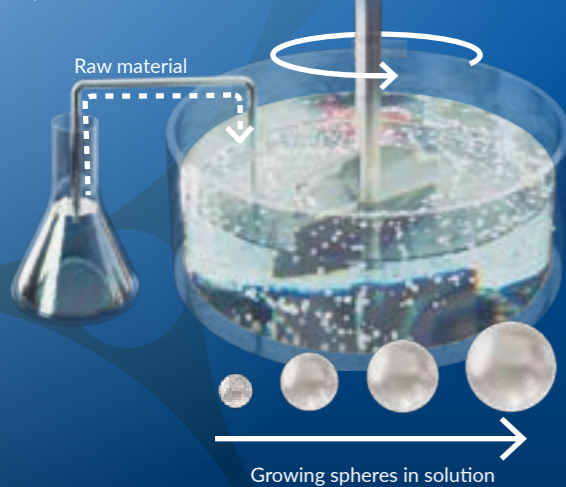
Spherical fillers – combining aesthetics and resilience

An intensively thought-out and innovative development concept has given rise to the exceptional composites ESTELITE and OMNICHROMA. Size- and shape-controlled spherical sub-micro fillers obtained in a fine manufacturing process (Sub-Micro-Pearl-Technology) set new standards for aesthetic composite restorations. Many years of development of the manufacturing process for fillers with special aesthetic, resilient and user-friendly properties are the basis for the outstanding result.

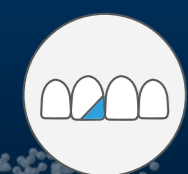
Thanks to the unique fillers, ESTELITE as well as OMNICHROMA, are extremely user-friendly to work with, as they do not stick to the spatula and are easy to polish.

The production – Sol-Gel vs. Conventional grinding process

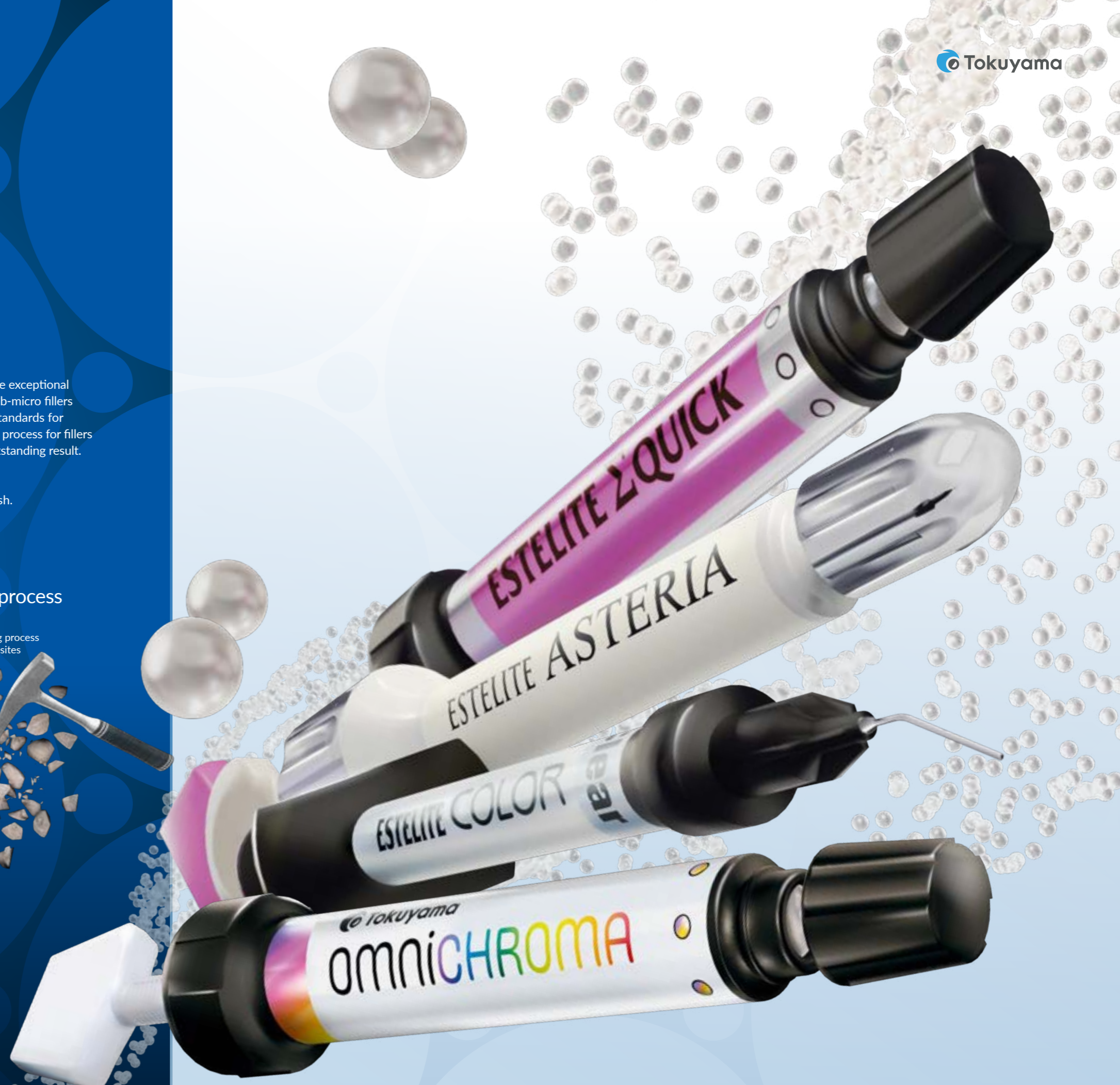Growing size and shape-controlled spherical fillers



The uncontrolled grinding process of fillers in regular composites



- Distinct chameleon effect & unique aesthetics
- Excellent polishability & gloss
- Universal composites and specialists for all indications



OMNICHROMA

1000 Shades of White – all in 1 single syringe!
Infinitely colour adjustment from A1 to D4.

Structural colour

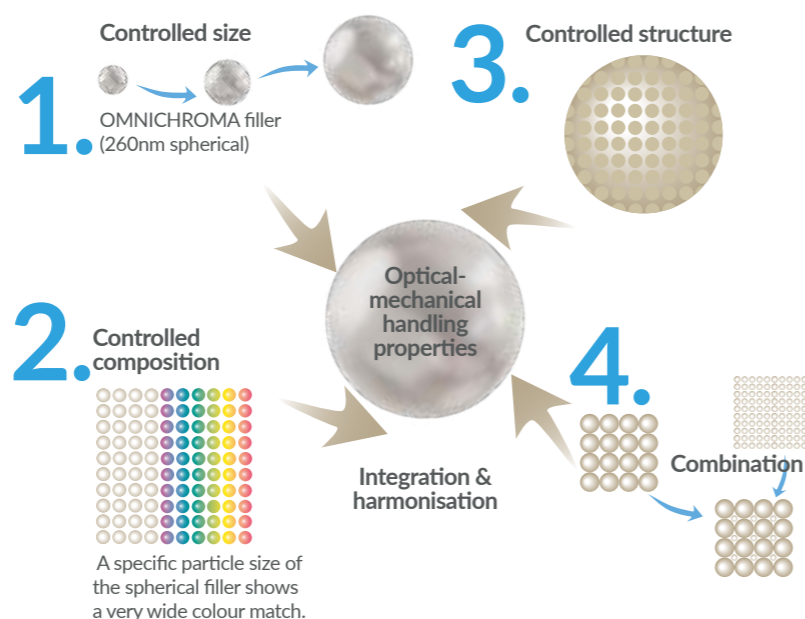
Natural colouring without artificially added colour pigments thanks to Smart Chromatic Technology. Bis-GMA-free formulation for increased biocompatibility.

Simplified stockpiling

Order and store only one colour – always the right colour at hand. No more expired special colours.

Time saving

No tedious and time-consuming colour determination – start immediately.



OMNICHROMA BLOCKER

The ideal supplement to OMNICHROMA if the automatic colour matching could be compromised.

Support


Provides an additional shade when the natural shade of the tooth is not present in larger defects.

Discolourations

Reliably covers disturbing colour influences, e.g. after amalgam removal.

Oral cavity

Prevents disturbing colour influences from the oral cavity and prevents greyish shimmer.



"Every dentist's dream comes true: always the right colour at hand!"



Drs. Erik-Jan Muts, Apeldoorn (NL)

"Amalgam tattoos and endocavities can be reliably covered with the Blocker. The layer thickness depends on the degree of discolouration and the depth of the cavity."

Dr. Tom Verhofstadt, Kevelaer (GER)



OMNICHROMA FLOW

The logical further development of OMNICHROMA – 1000 Shades of White in 1 single syringe, also as a flowable type.

Structural colour

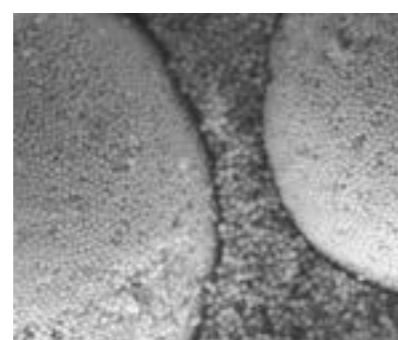
Natural colouring without artificially added colour pigments thanks to Smart Chromatic Technology. Bis-GMA-free formulation for increased biocompatibility.

Flowability


Optimum flow behaviour and excellent cavity adaptation.

Load capacity

Suitable for both anterior and posterior teeth thanks to excellent physical properties.



OMNICHROMA FLOW
(TOKUYAMA DENTAL; 1µm; 5,000x magnification)



Venus Flow One, Kulzer
(1µm; 20.000x magnification)

OMNICHROMA FLOW BLOCKER

The tried and tested OMNICHROMA BLOCKER against disturbing colour influences – also available as a flowable type.

Opacity

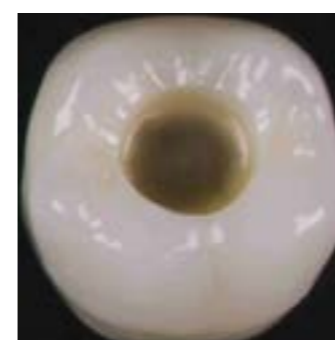
Reliably eliminates interfering colour influences for an aesthetically correct colour match.

Flowability

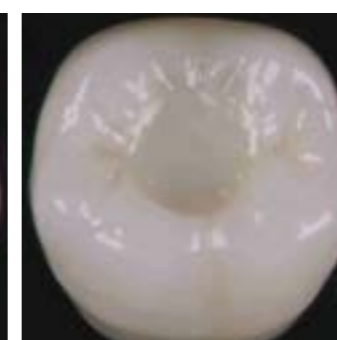Optimum flow behaviour for rapid lining of posterior cavities.

Versatility

Universal cover shade for various indications.



With Chroma Zone Black



Blocker 1 mm

SAMPLE:



„The addition of a flow variant to this product idea is absolutely to be welcomed and rounds off the application possibilities excellently.“



Prof. Dr. Claus-Peter Ernst,
Mainz (GER)

INFO:



“The use of the blocker requires a little bit of intuition, but even anterior restorations can be solved excellently with OMNICHROMA.”

Dr. Christof Föcking,
Isselburg-Anholt (GER)



OMNICHROMA FLOW BULK

Completes the OMNICHROMA family –
1000 Shades of White all in 1 single syringe,
now also with depth curing.

Ultra-strong deep curing

Reliable curing of at least 3.5 mm increments.
Especially suitable for deep cavities.

Strong under pressure and stress

A free-flowing composite material with excellent compressive
strength in excess of 400 MPa. Maximum load-bearing capacity
even in large cavities and without an additional capping layer.

Low polymerisations shrinkage

The high filler content provides nearly identical shrinkage to pasty composites.



**Without artificial
colour pigments**
adapts "automatically"
to the tooth colour



**Bis-GMA –
free formulation**
for better
biocompatibility



**No capping
layer necessary**
excellent load-bearing
capacity



Typical laser microscope images of the individual cavity adaptations

Source: TOKUYAMA DENTAL R&D



Customers also bought this additional product:
OMNICHROMA Blocker Flow

More at
COMPOSITES >> OMNICHROMA BLOCKER FLOW



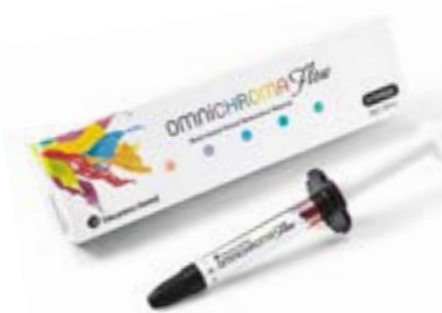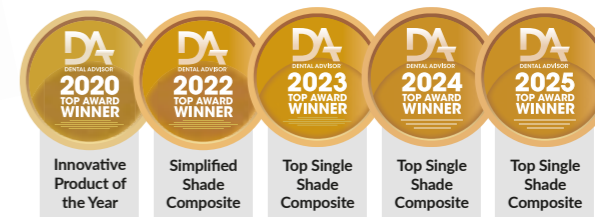Award-winning!

Not just good – multiple awards and distinctions:
Materials from TOKUYAMA DENTAL.



OMNICHROMA

Recognised as the biggest innovation in the dental
sector immediately after its launch, now the leading
one-shade composite.



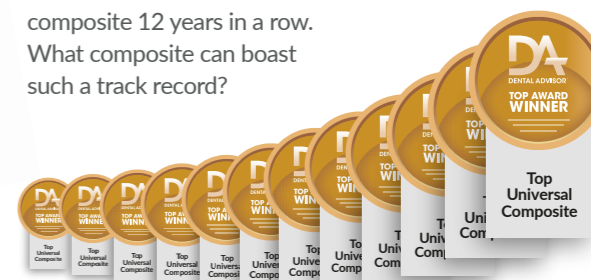OMNICHROMA FLOW

The flowable version OMNICHROMA FLOW is also a leader
in the field of single-colour composites or flowables.
Also recognised as a problem solver for invisible aligner fixings.



ESTELITE SIGMA QUICK

A class of its own. Awarded best universal
composite 12 years in a row.
What composite can boast
such a track record?



ESTELITE ASTERIA

An innovative and highly simplified layering concept for maximum aesthetics – perfect restorations are achieved for every user.

Enhanced chameleon effect

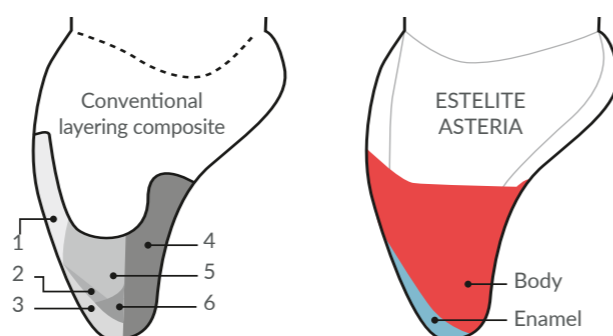
Increased light diffusion inside the material leads to a pronounced chameleon effect. Only a few basic colours are sufficient for a highly aesthetic result.

Simplified layering technique

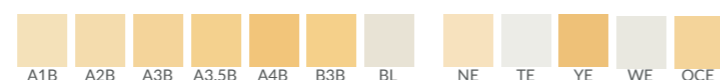
Optimally coordinated dentine shades with increased opacity and enamel shades with increased translucency. Restorations with strong character even without complex layering techniques.

Optimum gloss

Spherical fillers that, thanks to their shape, can be polished in seconds – for outstanding aesthetics.



Shades – 12 (7 dentine shades – 5 enamel shades):



ESTELITE COLOR

Expressive tints for individual characterisation of the respective restoration.

Colours

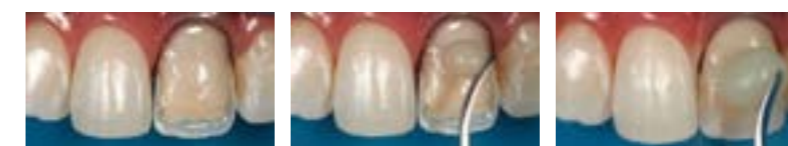9 different shades make teeth look younger or older. Even fissures or pits can be imitated naturally.

Opaque

4 special opaque shades provide reliable coverage of heavily discoloured areas. Also suitable for covering metal or for repairs.

Flowability

Due to their consistency, the tints are easy to apply and can be individually shaped with a small probe or the TOKUYAMA brushes.



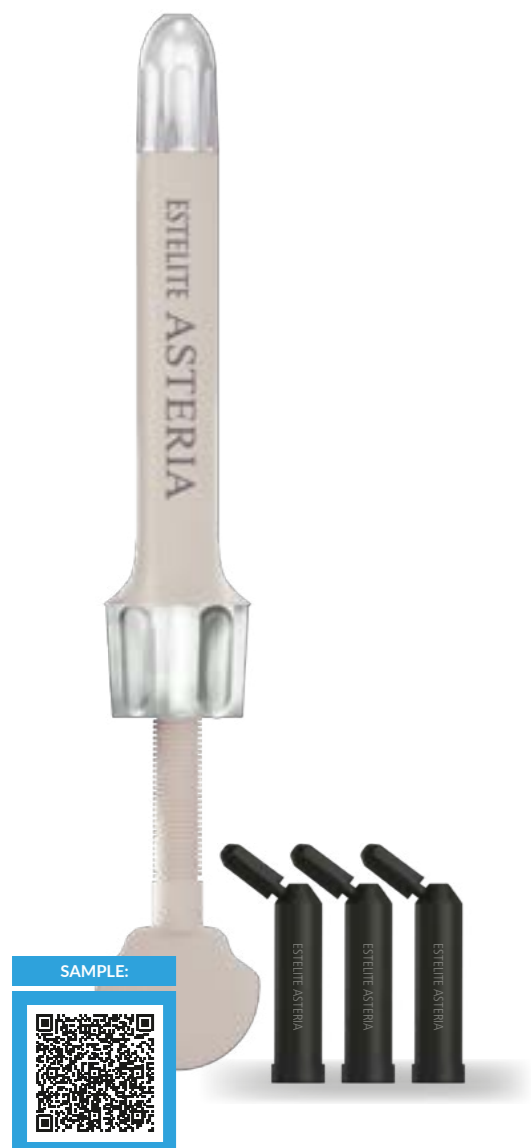
ESTELITE COLOR MCO is applied evenly over the discoloured areas to raise the colour value.

After light curing, a layer of dentine shade with the desired shade and saturation is applied over the opaquer.

After light curing, the enamel shade is applied.

(Pictures: Dr. Newton Fahl Jr.)

Shades – 13:



"Thanks to the unique spherical filler technology, glossiness of the surface remains very good after more than 3 years."



Dr. Milan Lehotsky, Bratislava (SK)



Customers also bought this additional product:

Brush No.24

More at >> www.tokuyama-dental.eu

ESTELITE SIGMA QUICK

The classic – our award-winning universal composite for all requirements and indications.

Excellent

Awarded best universal composite by Dental Advisor 12 years in a row – for highest demands on gloss, aesthetics and polishability.

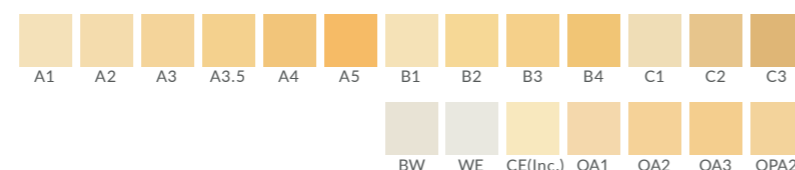
Strong chameleon effect

Strong in colour matching – this is how restorations that blend harmoniously and invisibly into the tooth environment can be achieved even without complex preparations.

RAP-Technology

Radical Amplified Photopolymerisation – this is the magic formula for accelerated curing with a high conversion rate at the same time.

Shades – 20:



ESTELITE POSTERIOR

Strong under pressure – when a particularly resilient material is required for the posterior region.

Novel combination

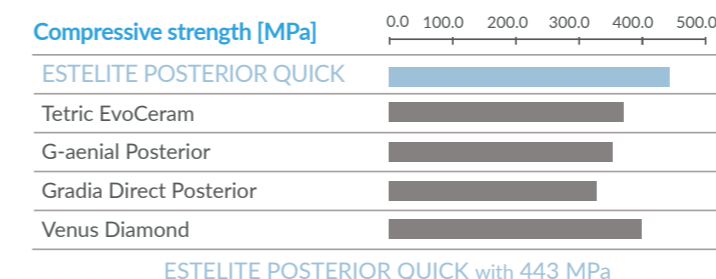
A combination of spherical and classic ground fillers creates an optimal filler distribution – for a high filler content.

Radiopacity

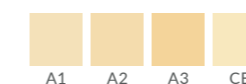Highly visible filler particles allow optimal control of the placed fillings – for a safe feeling.

Resilience

High E-modulus, strong compressive strength – optimal physical values for the strongest loads, whether crunchers or not.



Shades – 4:



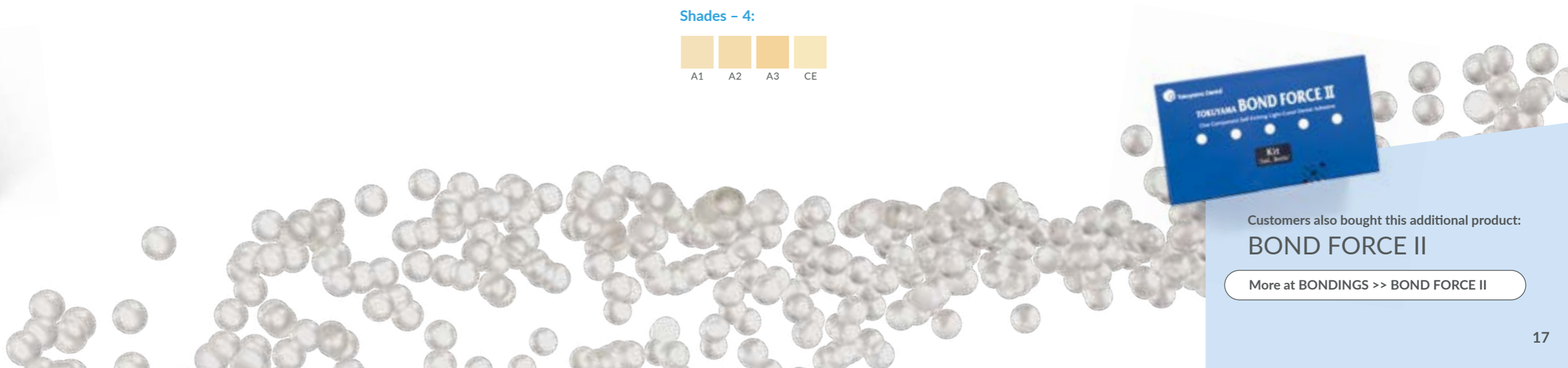
Source: TOKUYAMA DENTAL R&D

Customers also bought this additional product:
UNIVERSAL BOND II

More at BONDINGS >> UNIVERSAL BOND II

Customers also bought this additional product:
BOND FORCE II

More at BONDINGS >> BOND FORCE II



Renewal of a composite restoration

Treatment of a discoloured, previously traumatised vital tooth 11



Dr. Nicolò Barbera,
University of Geneva (CH)

A 30-year-old patient, with a negative medical history, comes to attention with the request to replace the previous composite reconstruction performed 10 years earlier following a trauma of UR1.

UR1 on clinical examination is responsive to the viability test, and does not present periapical lesions on the radiograph performed on the same day (Fig. 1).

UR1 is discoloured and in a more palatal position than the contralateral central UL1 (Fig. 2).

The aesthetic analysis highlights an asymmetry of the gingival zenith between UR1 and UL1. Through the use of a periodontal probe, after plexus anesthesia, the altered passive eruption of the type IA junctional epithelium is confirmed according to the classification of Coslet et al. (Fig. 3).

With a view to carrying out the most conservative restorative treatment possible on the patient, taking into

account the age and vitality of the retained dental element, it is decided to carry out a direct composite restoration following planning and a diagnostic wax-up of the case.

On the day of treatment, following local plexus anesthesia, UR1 is isolated using a rubber dam sheet, extending the isolation to the first premolars (Fig. 4).

Subsequently, the fractured composite reconstruction is removed and a short bevel is performed on the preparation and the entire surface of UR1 is sand-blasted with 27µm aluminum oxide powder (Fig. 5).

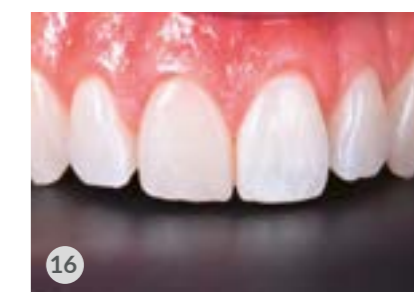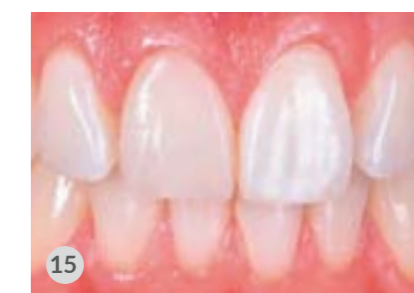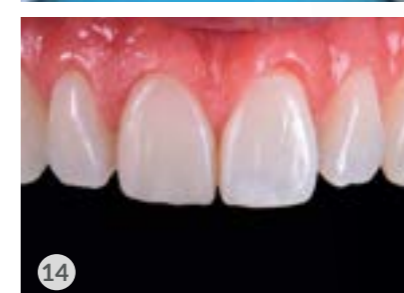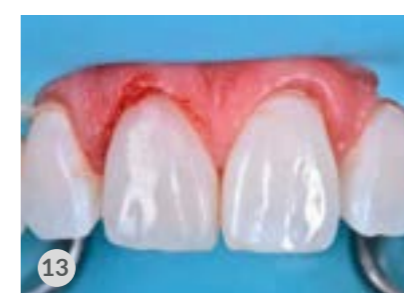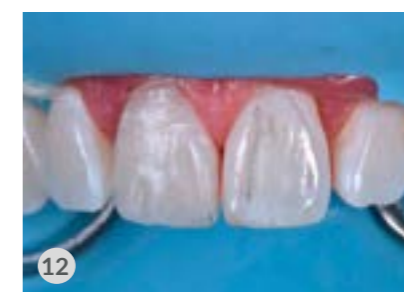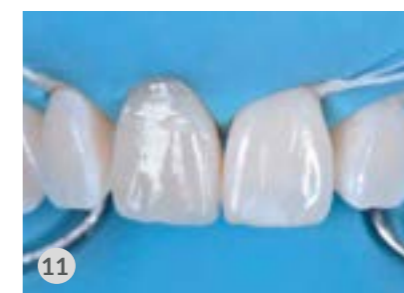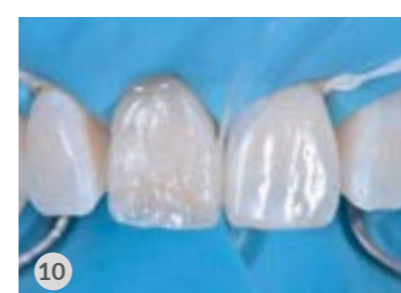

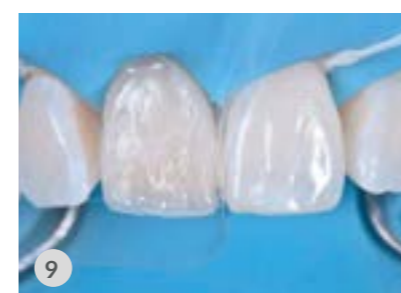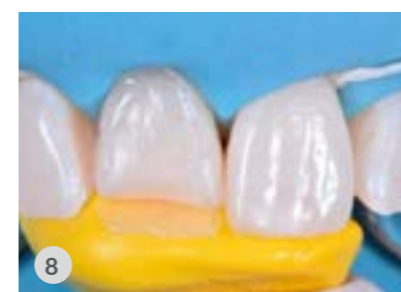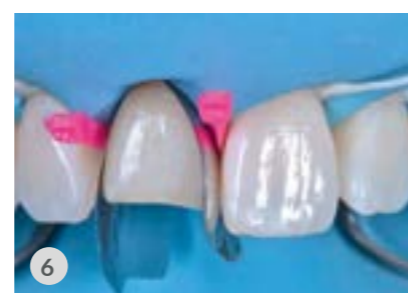
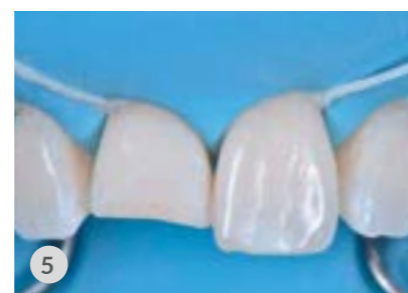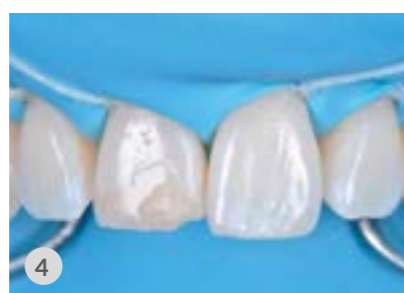
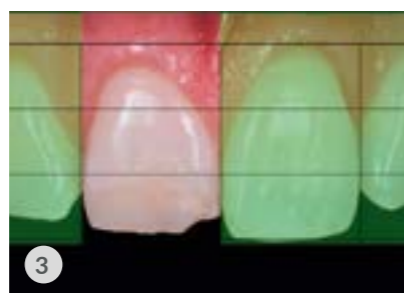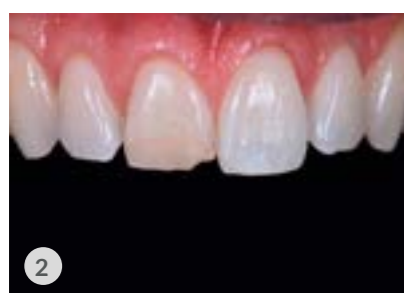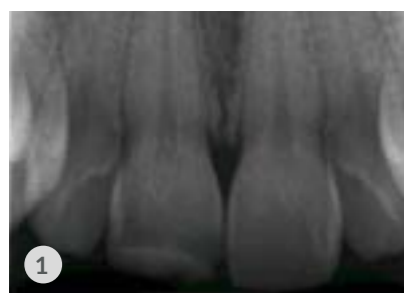In order to correct the altered passive eruption, it was decided to recreate the emergence profile of the tooth by accentuating the vestibular bulge and

seeking symmetry with the contralateral element. For this purpose, a pre-formed metal matrix is used and is blocked with two wedges.

Once the matrix has been adapted, the adhesion procedures are carried out with a 3-step etch&rinse system. Each step is followed by polymerisation with UV light for 40 seconds (Fig. 6).

The vestibular emergency profile is recreated with an enamel shade of composite (Fig. 7).

After performing a silicone index of the diagnostic wax-up, the palatine wall is reconstructed by an enamel shade of composite (Fig. 8).



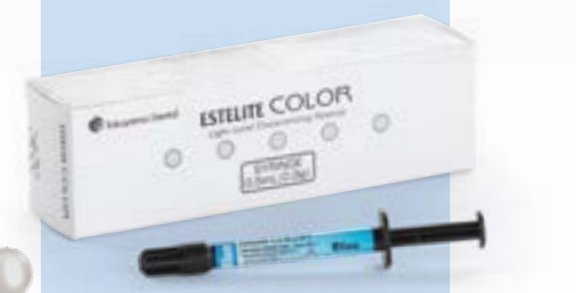These products were used:



ESTELITE ASTERIA



ESTELITE SIGMA QUICK



ESTELITE COLOR

Subsequently, the dentinal anatomy is reconstructed through the reproduction of the mamelons with an opaque dentinal composite shade; this shade will also be fundamental for correcting the shade of the dischromatic element (Fig. 9). Light blue and white effect shades are applied to emulate the opalescence in the incisal area (Fig. 10).

The layering is completed through the use of an enamel shade in the vestibular with a single addition. The vestibular surface is modelled and controlled in three-dimensional volumes in order to have as few final adjustments as possible. It is then polymerised for 20 seconds and polymerised for 40 seconds in the vestibular and palatine after being

covered with glycerin gel to inhibit the hybrid layer of the composite (Fig. 11).

The finishing and polishing procedures are carried out trying to emulate the transition lines of UL1 (Fig. 12 / 13).

The patient is checked again after 21 days (Fig. 14/15) and 12 months (Fig. 16) to evaluate the aesthetic result in shape and colour.



ESTELITE UNIVERSAL FLOW

Simply flowable? No, triple flowable
for all indications and preferences.

3 Viscosities


Different viscosities always offer the user
the ideal choice for every occasion.

Increased light diffusion

Increased light diffusion causes a strong scattering of the incident
light inside the material. This creates a pronounced chameleon effect
for a minimum of colours.

Resilience

The combination of round composite fillers and spherical fillers
ensures strong resilience – comparable to pasty composites.



SuperLow

Stable against
uncontrolled flowing
away



Medium

Universally applicable
for all indications

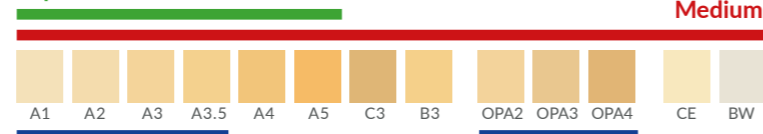


High

Ideal for fissures
or for lining

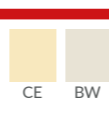
Shades – 12:

Superlow



High

Medium



ESTELITE BULK FILL FLOW

Deep curing at the touch of a button –
reliable and relaxed without stress.

Novel composite filler


Spray granulation creates an edgeless composite filler from the spherical fillers –
round fillers for reduced polymerisation stress with simultaneous deep curing.

Controlled refractive index

Initially translucent for a deep cure the refractive index reverses
upon curing – for an opaque and aesthetic result.

No capping layer

The novel combination of fillers ensures optimal resilience.
The controlled refractive index ensures an appealing result.
Two reasons why the otherwise obligatory capping layer can be omitted.

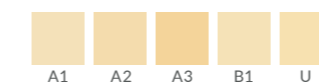

ESTELITE BULK FILL FLOW:
Composite filler ("edgeless")



Conventional composite:
inorganic fillers (irregular)

Shades – 5:



„Always the right viscosity
with perfect polishability
make this flow the agent
of choice.“



Dr. Markus Lenders,
Nettetal (GER)



Customers also bought this additional product:
BOND FORCE II PEN

More at BONDINGS >> BOND FORCE II PEN

Tooth reshaping with composite

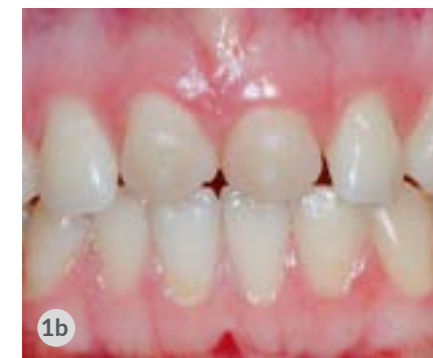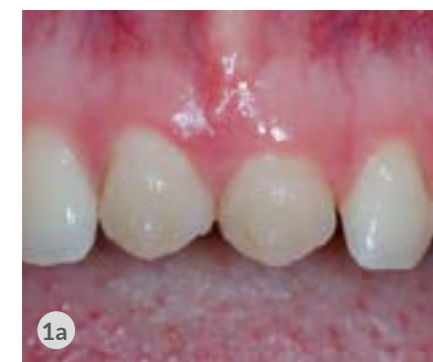Tooth reshaping with composite after tooth transplantation in the anterior region



Prof. Dr. Anne-Katrin Lührs,
Hannover (GER)

History: After a fall in a swimming pool in 2000 and a total dislocation of the two central incisors 11 and 21 (both teeth were lost in the fall), teeth 34 and 44 were transplanted in region 11 and 21. Seven years later, the patient, who had been satisfied with the restoration up to that point, presented for a consultation regarding the further restoration of the transplanted premolars. Orthodontic treatment with regular radiographic control of region 11/21 was carried out in parallel. The apical region of the transplanted premolars was inconspicuous, there was no evidence of root resorption.

Fig. 1a, b: Transplanted premolars in region 11/ 21, composite copings from orthodontic treatment still in situ



Treatment planning: After evaluating the clinical and radiographic findings, the plan was to minimally invasively reshape the grafted premolars 34 and 44 into central incisors. Other treatment alternatives such as the fabrication of all-ceramic veneers and the performance of a surgical crown lengthening (vestibular) to harmonise the gingival line were rejected by the patient for reasons of invasiveness.

Treatment procedure: First, a wax-up (Fig. 2) was made to inform the patient about different treatment options and to evaluate the expected loss of substance due to preparation measures.

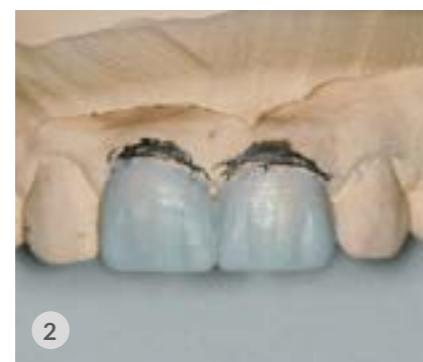

Fig. 2: Wax-up of region 11/21 and drawn-in suggested course of the gingival margin after surgical crown lengthening.

Based on the silicone key fabricated on the wax-up, an intraoral mock-up was fabricated with a provisional plastic material to visualize the targeted treatment results. Due to the thickness of the wax-up and the position of the transplanted premolars in the dental arch, it was

agreed with the patient, who was very satisfied with the mock-up, to shape the restoration more delicately in a vestibular direction.

The teeth were now cleaned with fluoride-free prophylaxis paste. Then the shade was selected and

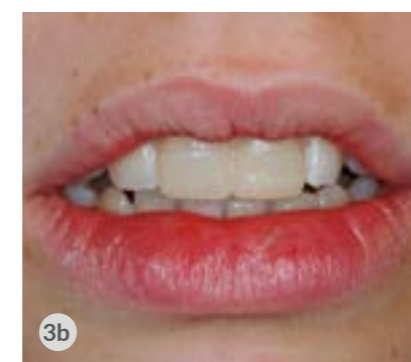
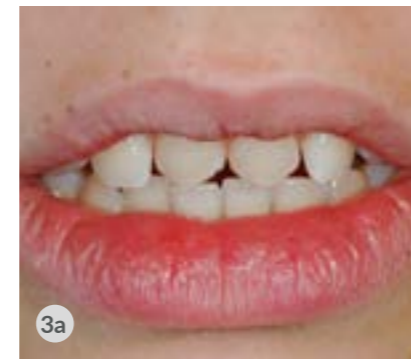
Fig. 3a, b: Situation after removal of the composite flaps (a), intraoral mock-up for visualisation of the possible treatment result (b).

the material ESTELITE SIGMA QUICK (TOKUYAMA DENTAL, Metelen) was used as the composite system.

This system contains an extra-opaque dentine material, OPA2, which was used to build up the incisal dentine core that is not supported by tooth structure.

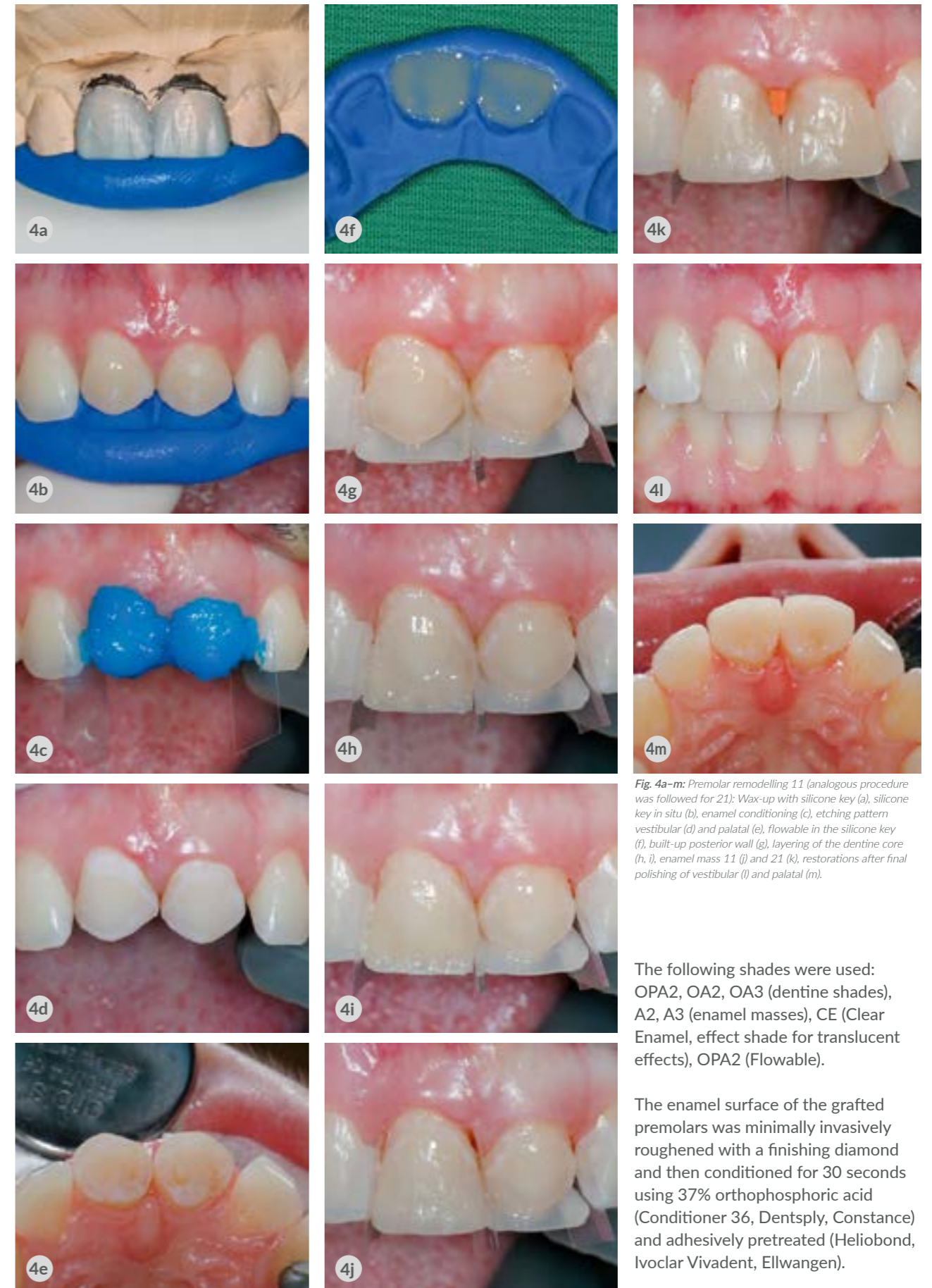

Fig. 4a-m: Premolar remodelling 11 (analogous procedure was followed for 21): Wax-up with silicone key (a), silicone key in situ (b), enamel conditioning (c), etching pattern vestibular (d) and palatal (e), flowable in the silicone key (f), built-up posterior wall (g), layering of the dentine core (h, i), enamel mass 11 (j) and 21 (k), restorations after final polishing of vestibular (l) and palatal (m).

The following shades were used: OPA2, OA2, OA3 (dentine shades), A2, A3 (enamel masses), CE (Clear Enamel, effect shade for translucent effects), OPA2 (Flowable).

The enamel surface of the grafted premolars was minimally invasively roughened with a finishing diamond and then conditioned for 30 seconds using 37% orthophosphoric acid (Conditioner 36, Dentsply, Constance) and adhesively pretreated (Heliobond, Ivoclar Vivadent, Ellwangen).

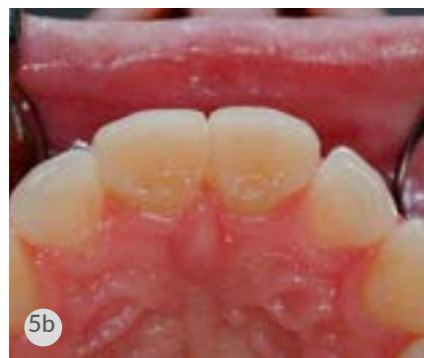
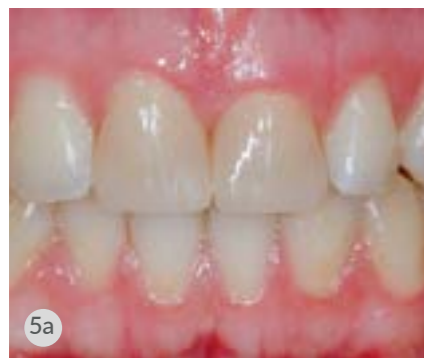
Fig. 5a, b: Clinical situation 4 weeks postoperatively, view from vestibular (a) and palatal (b)

With the help of a silicone key, the posterior wall was now built up from the flowable of shade OPA2 in a thin layer thickness. The different dentine materials were then modelled in several layers: OPA2 as opaque core, OA3 cervical and OA2 incisal.

An approx. 1 mm wide area was left free in the area of the incisal edge, which was filled with a thin layer of effect material (CE). A very thin layer of OA2 was added directly to the incisal edge to achieve the "halo effect". The dentine core was then coated with the enamel materials (A2 incisal, A3 cervical).

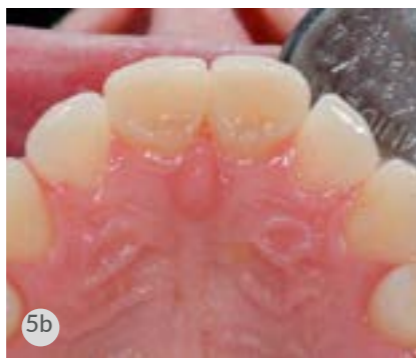
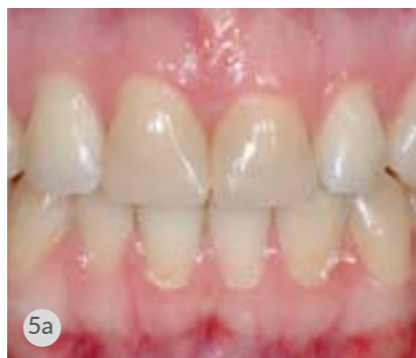
Fig. 6a, b: Reshaped premolars after 4.5 months postoperatively, view from vestibular (a) and palatal (b)

After final polishing, the teeth were fluoridated (Biflourid, Voco, Cuxhaven).

The illustrations above show the restorations at follow-up appointments after 4 weeks, 4.5 months and 14 months.

Follow-up sessions were arranged with the patient at 6-month intervals after completion of treatment.

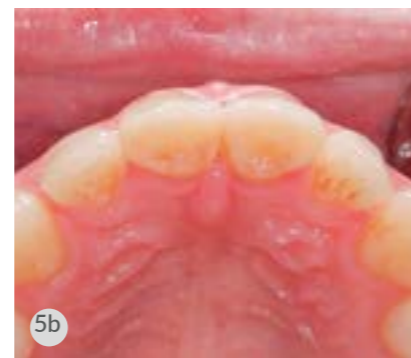
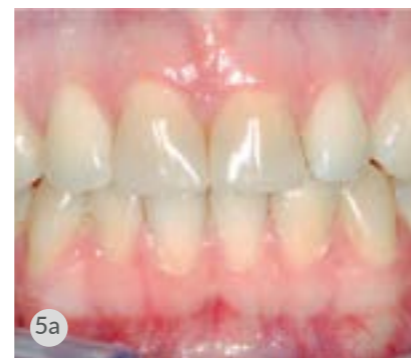
Fig. 7a, b: Composite restorations after 14 months postoperatively, vestibular view (a) and palatal view (b)

Epicrisis and discussion: The patient case presented represents the reshaping of two premolars after autogenous tooth transplantation following anterior trauma, in which both central incisors were totally luxated and were not available for replantation because they could no longer be found.

With regard to the reshaping of transplanted premolars into anterior teeth, there are individual case reports in which both composite restorations and all-ceramic veneers were fabricated as a therapeutic measure for tooth reshaping.

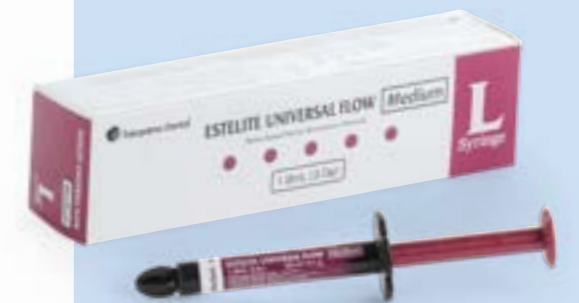In this case, minimally invasive composite restorations were fabricated at the request of the patient, who was informed about a wide variety of procedures. The posterior wall was built up from a very thin layer of Flowable using a silicone key after a previous wax-up. Since the occlusal contacts are in the area of the tooth structure, this procedure proved to be practicable.

The patient is satisfied with the treatment result achieved. During the observation period of 14 months, there were no indications of restoration failure.

These products have been used:



ESTELITE SIGMA QUICK

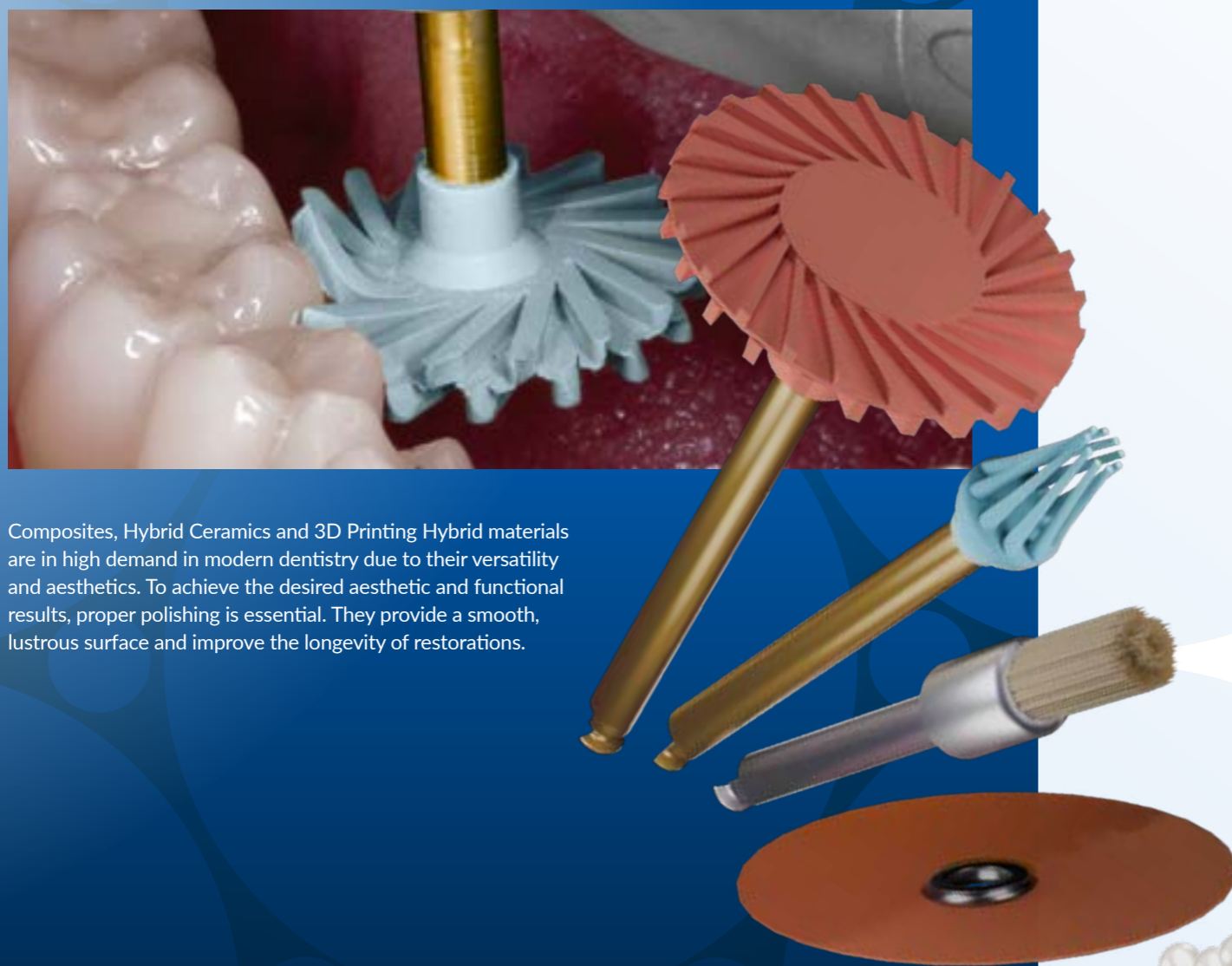

ESTELITE UNIVERSAL FLOW Medium

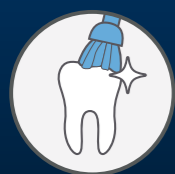POLISHER & BRUSHES

Modelling & Finishing-System
for composites to optimise
aesthetics and durability

First-class and efficient handling



Composites, Hybrid Ceramics and 3D Printing Hybrid materials are in high demand in modern dentistry due to their versatility and aesthetics. To achieve the desired aesthetic and functional results, proper polishing is essential. They provide a smooth, lustrous surface and improve the longevity of restorations.



- The polishing process is an important step at the end of every job.
- It represents the visual success of the restoration.
- Optimum match with TOKUYAMA's spherical filler.

Brush No.24

Brushes for exact composite modelling

Precision

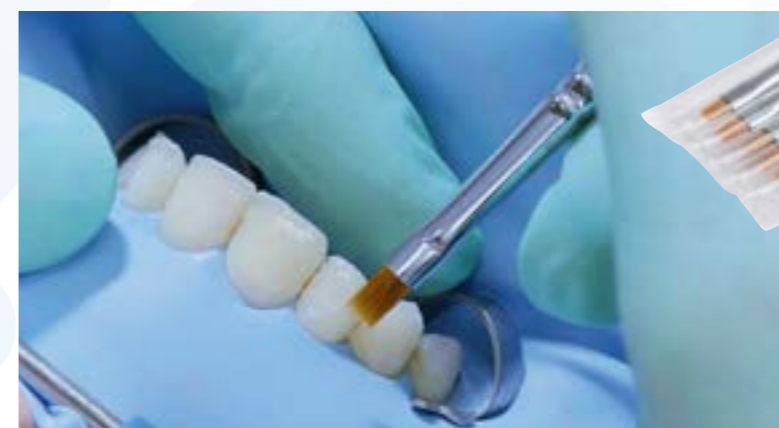Enables exact adjustments to the tooth structure before polymerisation.

Simplified Handling

Thanks to the non-stick properties, the composite does not stick to the tool. The brushes are autoclavable and reusable up to 10 times.

Aesthetics

Supports the creation of natural transitions, colour gradients and surface structures.



Lifelike modelling with
different brush ends.

Tokuyama Dental Brush No.24

Optimal incorporation
of tints.


More under COMPOSITES



ESTEPOLISHER[◆]

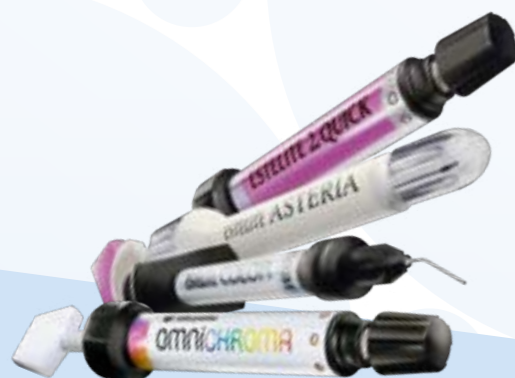NEW

Pre-polishing
MEDIUM High-shine polishing
FINE



Simplicity of polishing

- > 2-step polishing system for high-shine on all composite materials
- > Polishers specifically adapted to each processing step
- > Best results even on very hard composites



Adapted for all our composites with spherical fillers.

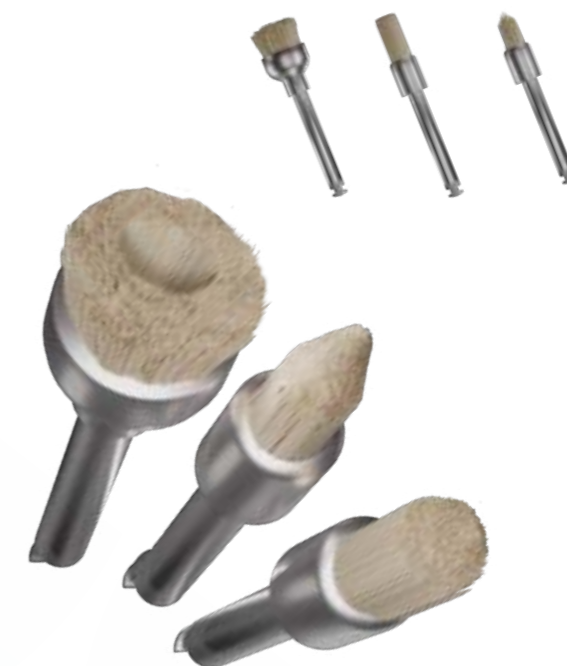More under COMPOSITES

ESTEBRUSH

NEW

Polishing to a high gloss

- > For high-shine polishing on composite and occlusal fillings
- > Application without polishing paste
- > Heat resistant and autoclavable polyamide fibre with silicon carbide grit



ESTEDISC

NEW

Flexible polishing system in 4 steps

- > Flexible polishing discs coated with aluminium oxide (single side)
- > For surface preparation and interproximal polishing
- > For use in a pulling or pushing motion

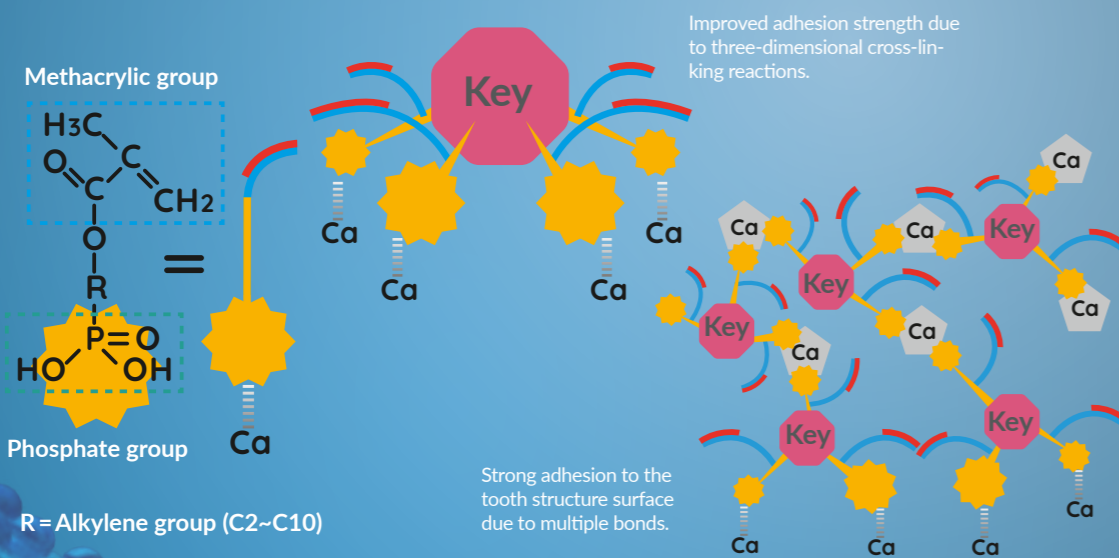


Available in 2 sizes:

	10 mm	14 mm
Shaping COARSE		
Smoothing MEDIUM		
Pre-polishing FINE		
Polishing EXTRA FINE		

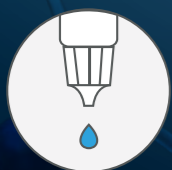ADHESIVES

The 3D-SR-Monomer –
a self-reinforcing adhesive monomer



The extraordinary adhesive strength of TOKUYAMA adhesive systems is based on a technologically unique monomer, which has been modified and optimised in the 2nd and 3rd generation, so that additional reaction chains of different lengths form various multiple bonds on the molecule and produce an extremely strong and tear-resistant adhesive layer in a very short time.

Through numerous chemical and mechanical bonds to the apatite of the tooth surface and the calcium ions of the tooth substance, the self-reinforcing monomer creates a 3-dimensional network. In addition, the latest generation of the 3D-SR-Monomer has the well-known adhesive monomer 10-MDP, which has been proven to form strong adhesive mechanisms.



- Reliable adhesion through innovative technologies
- Quick and easy application to minimise application errors
- Universal allrounders or special adhesives for special indications

UNIVERSAL BOND II

The bedrock of dental restorations –
standardised application on any surface.

No light curing

UNIVERSAL BOND II reacts by contact curing (BoSE technology).
This eliminates the usual light curing and saves time during application.

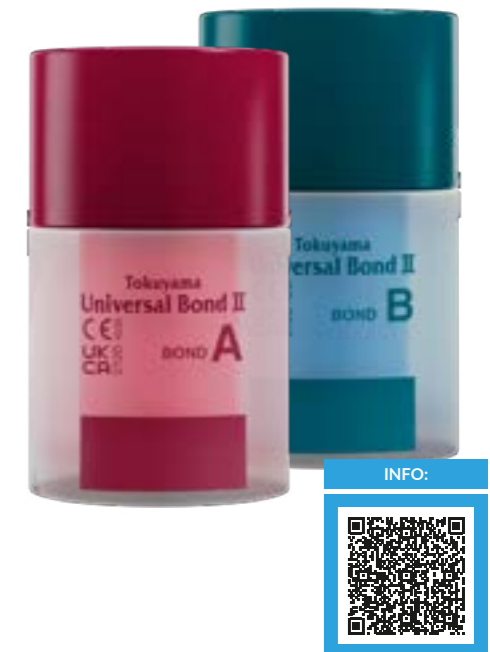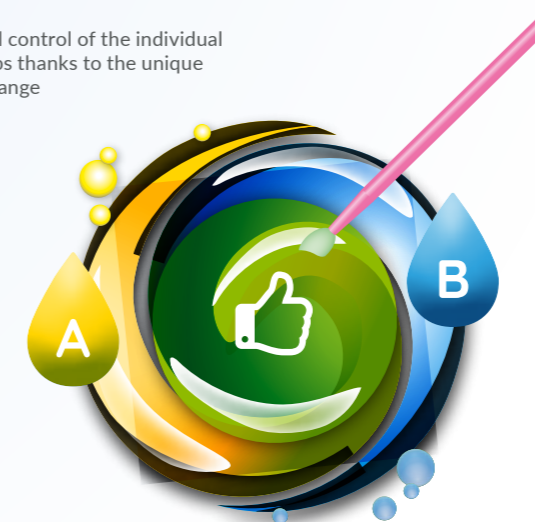
Standardised work

No matter which surface – just 3 steps apply:
Mix – Apply – Air blow – DONE! This minimises errors.

Visual control

The cleverly coloured liquids show the user the individual steps
via colour change – full control.

Full visual control of the individual
work steps thanks to the unique
colour change



The new UNIVERSAL BOND II from TOKUYAMA DENTAL can rightly be called universal bonding. It is easy to handle and achieves comparable results to previous bonding systems with fewer working steps. In combination with ESTEC EM II PLUS, it was possible to realise an aesthetically good restoration for our patient."



Gordon Kautzsch,
Leipzig (GER)



BOND FORCE II

All-in-One – the reliable 7th generation adhesive.

Quick

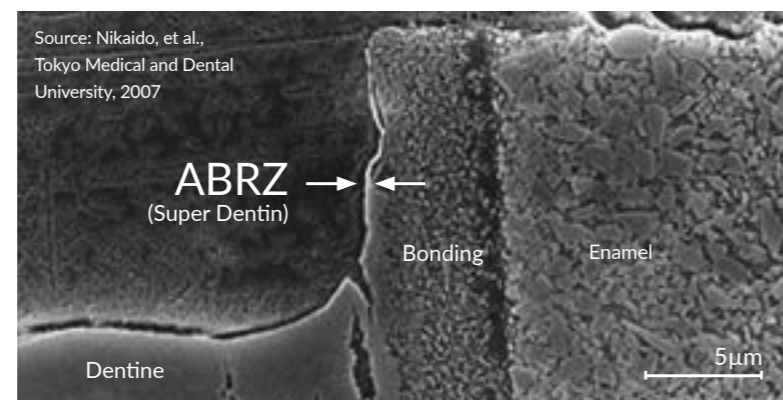
Only 25 seconds – this is how quickly the adhesive conditioning of the cavity can succeed.

Reliable

The innovative 3D-SR-Monomer forms a uniformly thin film layer – ideal cavity adaptation.

Fluoride release

A constant release of fluoride from the adhesive protects against postoperative sensitivities and secondary caries.



Super-Dentine

Due to the chemical reactions of the functional monomer, so-called “super dentine” is formed in the adjacent dentine layer, which is resistant to acid and base attacks and thus protects the tooth from secondary caries.



Customers also bought this additional product:
ESTELITE POSTERIOR

More at COMPOSITES >> ESTELITE POSTERIOR

BOND FORCE II PEN

Precise dosing at the push of the button.

Ball pen

Easy to use – just 2 clicks are enough to dispense the required material in a hygienic and user-friendly way.


Safe'n Easy principle

The pen is securely closed with a simple twist of the cap. The filling level can be easily read in the viewing window.

Application quantity

The application quantity is always dispensed in uniform drops, so that ideal economical dosing is possible. This avoids surpluses and guarantees gentle handling of the material.

Precise dosing



e.g. for small and medium-sized cavities



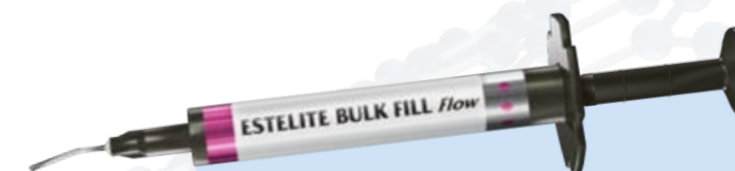e.g. for large cavities

Simply click and dose

Level indicator



INFO:



Customers also bought this additional product:
ESTELITE BULK FILL Flow

More at COMPOSITES >> ESTELITE BULK FILL Flow

Achieving “More Dental Show” with Advanced Composite Veneers



Freek Gols Linthorst (MSc),
Amsterdam (NL)

A patient-centered, minimally invasive approach to restoring self-confidence and natural smile aesthetics

A patient presented with a history of significant tooth wear caused by erosion and bruxism, resulting in shortened teeth and aesthetic concerns. She expressed dissatisfaction with the crowding in her upper anterior teeth and the discoloration of tooth 25 (Figure 1). Her primary request was for “more dental show” while ensuring the restorations retained the natural appearance of her teeth.

The treatment plan focused on restoring the natural proportions and aesthetics of the anterior teeth while respecting their current alignment and accommodating future orthodontic correction. Tooth 25 was managed with an internal bleaching plan after restoring the front teeth to harmonize the overall smile. TOKUYAMA'S ESTELITE UNIVERSAL FLOW, ESTELITE ASTERIA, and ESTELITE COLOR were selected for their excellent handling properties, high polishability, and ability to achieve lifelike translucency and depth. These materials facilitated a minimally invasive approach that delivered precise and aesthetically pleasing results while addressing the patient's functional and cosmetic concerns.

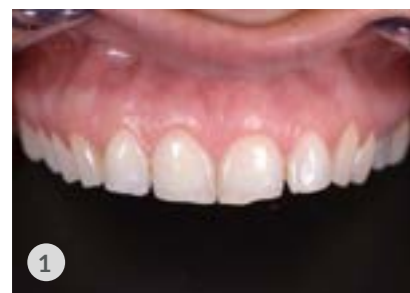

Fig. 1: Baseline condition with visible tooth wear, crowding and discoloration of tooth #25

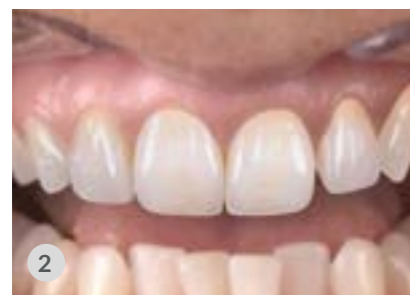

Fig. 2: Digital smile design to help visualize the planned outcome of the treatment

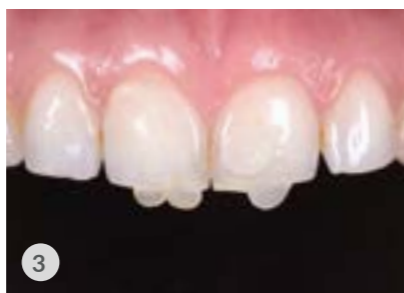

Fig. 3: Shade taking by means of a try-in of composite resin buttons

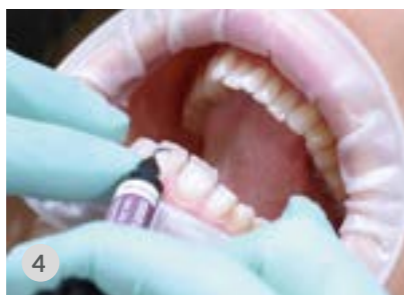

Fig. 4: Direct mock-up with flowable resin (ESTELITE UNIVERSAL FLOW), based on the digital smile design

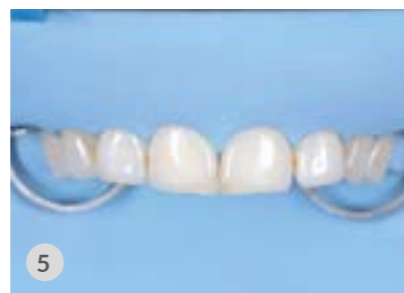

Fig. 5: Enamel bevels and rubberdam isolation of the anterior teeth

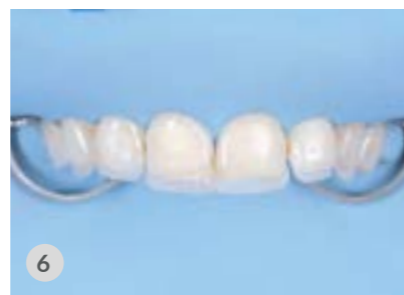

Fig. 6: A translucent palatal shell replicating natural enamel using ESTELITE ASTERIA TE shade

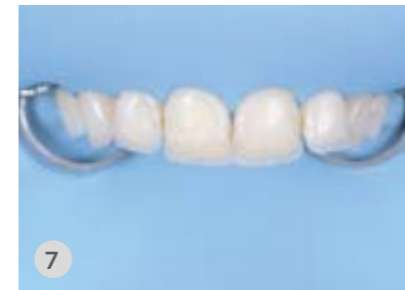


Fig. 7: The first layer of dentine mimicking composite using ESTELITE ASTERIA A2 Body shade (A2B)

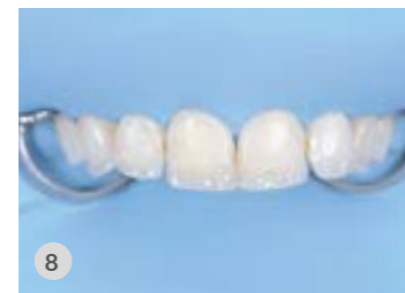

Fig. 8: The artificial halo in ESTELITE ASTERIA A1B shade and ESTELITE COLOR Clear application in between the dentine and halo layers

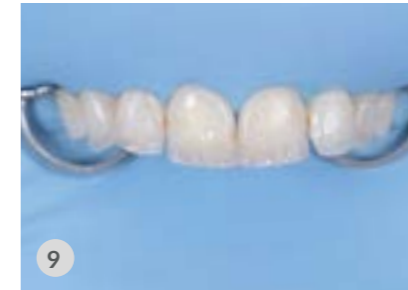

Fig. 9: Use of a ESTELITE COLOR Blue and Lavender mixture to achieve the right translucency shade

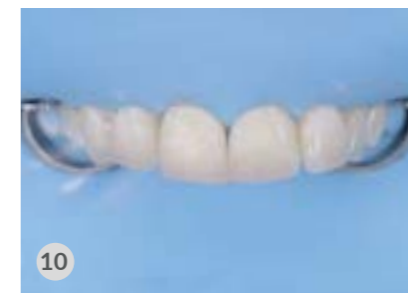

Fig. 10: Final layer of ESTELITE ASTERIA WE shade to finalize the layering procedure

Method

The treatment began with a digital smile design created using Apple's Key-note software, allowing visualization of the planned outcome and helping the patient understand the proposed changes (Figure 2). After reviewing and approving the design, the process advanced to shade selection, ensuring the optimal match for the patient's natural dentition. Once the shades were determined (Figure 3), the process moved forward to the mock-up phase.

To translate the digital design into the patient's mouth, a quick mock-up was created using ESTELITE UNIVERSAL FLOW (Medium, shade A2) (Figure 4). The material's medium viscosity ensured precise application, making it ideal for quickly visualizing the restorations. A putty index was fabricated from the mock-up to guide the layering

process, and the flowable composite was subsequently removed.

After removal of the mock-up, the teeth were isolated using a rubber dam to ensure a clean and dry working environment. This step optimized the adhesion process and improved vision and control during the composite layering. Minimal tooth preparation was performed, which included creating a minimal bevel and using air abrasion with Aquacare (Velopex). These steps facilitated optimal composite integration and enhanced the bond strength (Figure 5).

The enamel of the teeth was etched using phosphoric acid for 30 seconds and thoroughly rinsed with water for 30 seconds. BOND FORCE II was then applied, following the manufacturer's guidelines, to ensure optimal adhesion between the composite and the tooth surface.

The composite layering process was guided by principles of translucency and natural anatomy (Villarreal et al., 2011; Fahl, 2010; Fahl, 2015). A translucent palatal shell was created using ESTELITE ASTERIA TE shade to replicate the natural enamel's light transmission (Figure 6). Next, ESTELITE ASTERIA A2B shade was applied to create dentine mamelons, adding depth and character to the restoration (Figure 7). Following this, ESTELITE ASTERIA A1B shade was used to create the incisal halo, enhancing the natural appearance (Figure 8).

To further refine the optical properties, ESTELITE COLOR Clear was applied between the dentine mamelons and the incisal halo (Figure 8). This was followed by the application of ESTELITE ASTERIA BL shade to create natural internal effects. After the BL shade, little amounts of ESTELITE COLOR Blue mixed with ESTELITE COLOR Lavender tints were used to achieve the desired translucency shade in the area between the halo, mamelons, and internal effects (Figure 9). To reveal all the layering and effects, small amounts of the very transparent ESTELITE ASTERIA TE shade were applied over the incisal third of the restoration. Finally, ESTELITE ASTERIA WE shade was applied to complete the restorations, ensuring smooth transitions and a lifelike finish (Figure 10).

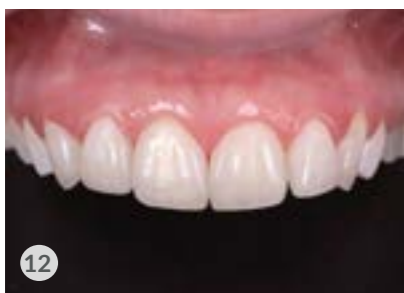
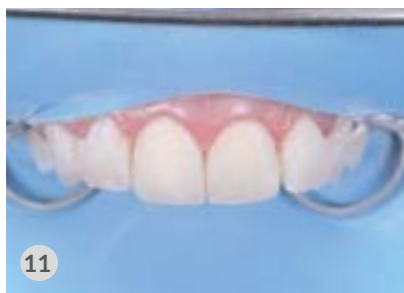
Fig. 11: View of the restorations after creating texture using different kind of burs and polishers

Fig. 12: Result after polishing

During the layering process, the TOKUYAMA BRUSH No.24 was used to shape and blend the composite seamlessly into the tooth surface before light curing each layer. This technique ensured a smooth integration of the composite and enhanced the natural appearance of the restoration.

The rubberdam was removed, and a new rubberdam was applied according to the "split dam approach". Restorations were then finished and polished using a sequential approach, beginning with polishing discs to refine the surface. Paper cones and Arkansas stones were used to create primary, secondary, and tertiary anatomy, ensuring the restorations mimicked the natural contours and textures of the teeth (Figure 11).

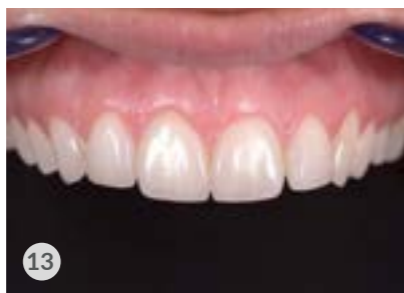

Fig. 13: Final result after internal bleaching of tooth 25

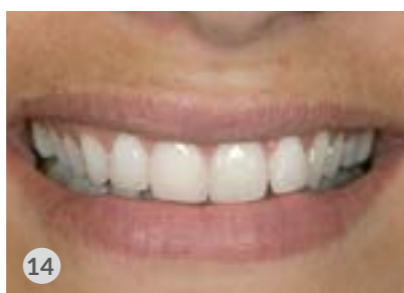

Fig. 14: Final result of the patient's smile

This process was completed using brownies and Occlubrush, achieving a high-gloss finish and optimizing both the durability and aesthetics of the restorations while ensuring seamless integration with the surrounding teeth (Figure 12).

During a second visit, the anterior restorations were slightly adjusted and polished again. Tooth 25 was prepared for internal bleaching to address its discoloration. This step was essential to harmonize the shade of the tooth with the newly restored aesthetics of the anterior teeth, achieving a cohesive and balanced smile (Figure 13&14).

Conclusion

This case highlights the successful use of ESTELITE ASTERIA and ESTELITE COLOR to create highly aesthetic and functional composite restorations. The unique spherical fillers of ESTELITE ASTERIA contribute to its exceptional polishability, ensuring that a high-gloss finish is easily achievable with proper finishing and polishing techniques. These fillers allow for a smooth surface and light reflection properties that closely mimic natural enamel, further enhancing the aesthetic integration of the restorations.

The incorporation of modern materials and techniques allowed for a minimally invasive approach, preserving the natural tooth structure while addressing the patient's concerns about tooth wear and aesthetics. The restorations have provided the patient with a functional and aesthetic foundation, preparing her for orthodontic treatment as the final step to achieving her beautiful smile.

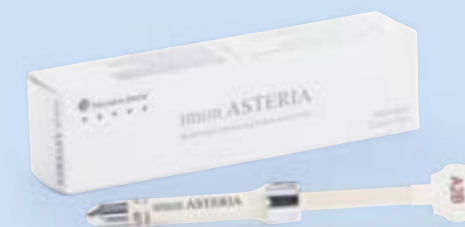The patient was highly satisfied with the results, noting the natural appearance and improved confidence in her smile. This case demonstrates how the advanced properties of ESTELITE ASTERIA, combined with careful planning and attention to detail, can achieve predictable and outstanding outcomes in composite veneer restorations.

References

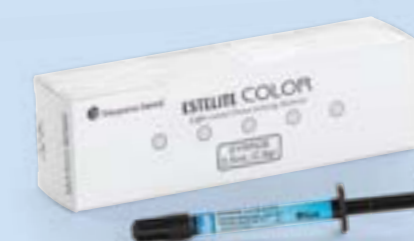- Villarroel M, Fahl N Jr, De Sousa AM, De Oliveira OB Jr. Direct esthetic restorations based on translucency and opacity of composite resins. Oper Dent. 2011;36(6):593-602. doi:10.2341/10-090-L
- Fahl N Jr. Mastering composite artistry to create anterior masterpieces: Part 1. J Esthet Restor Dent. 2010;22(4):219-234. doi:10.1111/j.1708-8240.2010.00356.x
- Fahl N Jr. A polychromatic composite layering approach for solving a complex class IV/direct veneer-restoration: Part 2. J Esthet Restor Dent. 2015;27(3):145-155. doi:10.1111/jerd.12178



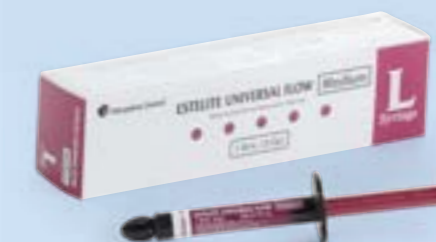These products have been used:



ESTELITE ASTERIA



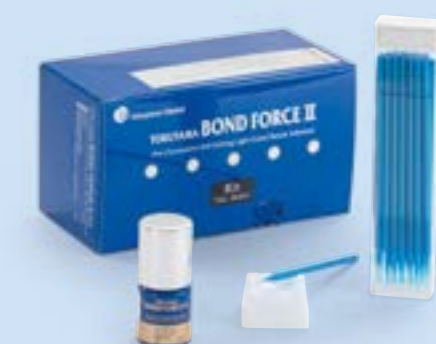ESTELITE COLOR



ESTELITE UNIVERSAL FLOW
Medium



TOKUYAMA Brush No.24



BOND FORCE II

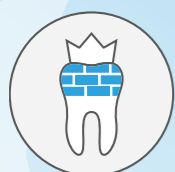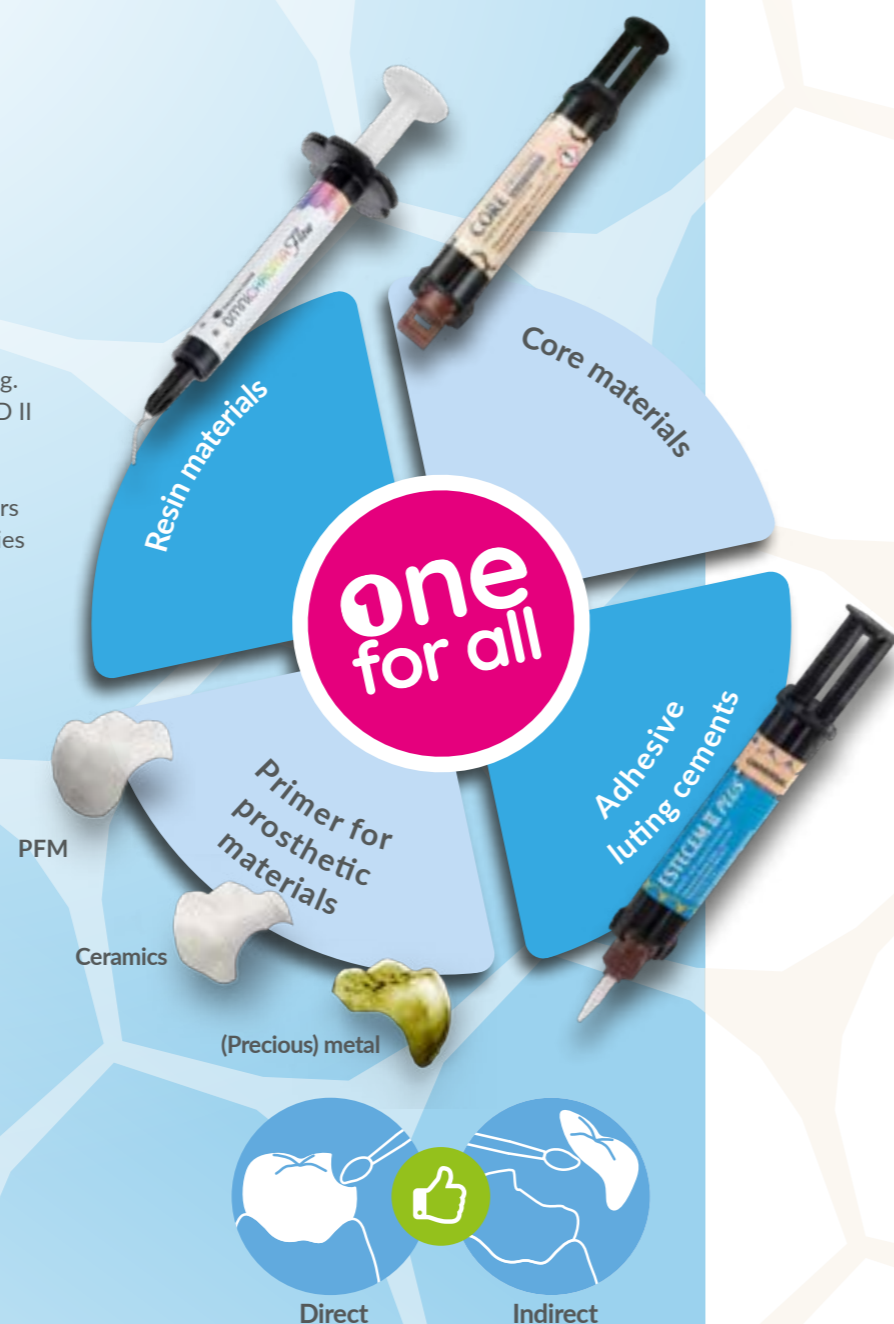CEMENT

BoSE Technology – the key to universal applicability and eliminating the need for light curing



ESTECM II PLUS is a composite cement for the entire indication spectrum of indirect luting. Thanks to the TOKUYAMA UNIVERSAL BOND II included in the system, ESTECM II PLUS can be used universally on all prosthetic surfaces without restrictions. Without additional primers or activators, the same procedure always applies to all surfaces: mix 1:1, apply, blow, done!

This is made possible by the patented BoSE Technology, which, compared to conventional benzoyl peroxide/amine systems, has a high catalytic activity even under acidic conditions. This achieves a standardised conditioning of all surfaces, which are ready for adhesive cementation thanks to contact curing – without further polymerisation.



- › Universally applicable
- › Reliable thanks to adhesive luting
- › Easy handling and working

ESTECM II PLUS

The adhesive allrounder – attaches indirect restorations regardless of the material.

Colour stability

Nearly insoluble after light curing - colour stability and no wash-out of the margin.

Viscosity

Ideal viscosity – no uncontrolled flow of the paste.

Handling


Good processing – easy removal of the excess.

Colour stability

	ESTECM II	RelyX Ultimate	Multilink Automix	Variolink Esthetic DC	Panavia V5	Panavia F2.0
Colour	Universal	A1	Yellow	Bright	Universal	Bright
Before Test						
After Test (24hours at 80 °C in coffee solution)						
ΔE	4.6	8.8	11.0	19.8	12.5	11.8

Source: TOKUYAMA DENTAL R&D


Shades – 4:



Customers also bought this additional product:
UNIVERSAL BOND II

More at BONDING >> UNIVERSAL BOND II

Universal adhesive as a substitute for hydrofluoric acid?



Good bonding values with adhesive and self-adhesive luting composites.

Due to its favorable mechanical and aesthetic properties, lithium disilicate has become established as a material for crowns, veneers and inlays, among other things. However, a suitable adhesive protocol is necessary to ensure that the bond to the tooth substance is as long-lasting and reliable as possible. Pretreatment of the restorative material plays a central role in this. In this context, the most recent study results from Japan show that the universal adhesive UNIVERSAL BOND II is an attractive alternative to hydrofluoric acid – and this with a high level of compatibility with other adhesive systems.

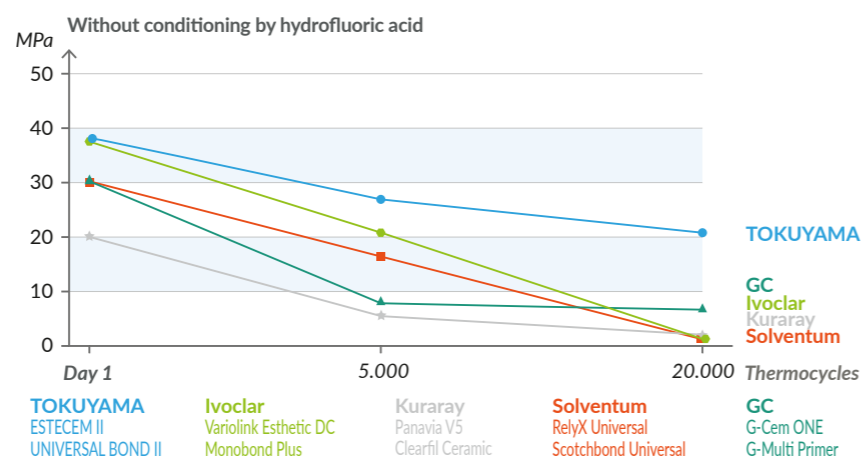
Etching the inner surfaces with 5% hydrofluoric acid gel has established itself as the standard procedure for the pretreatment of lithium disilicate restorations. However, unlike with other glass ceramics, the etching time here is only 20 seconds.¹ During this process, glass particles are dissolved out of the ceramic, creating a retentive etching pattern. This pattern forms the basis for the micromechanical anchoring between the ceramic and the luting composite.² In addition, subsequent silanization of the restoration surface improves the bond.

In addition to separate silane primers, universal adhesives with silane adhesion promoting agents can also be used for this purpose. These, in turn, are available in both one- and two-bottle versions. A current study from Japan looks at which of these two methods is preferable for achieving a long-term bond.³ In addition to its compatibility with various luting composites, the scientists were also interested in whether such a universal adhesive could be used to pretreat lithium disilicate, as a substitute for potentially harmful hydrofluoric acid.

One study, nine luting composites
For their investigation, the researchers

looked at the bond strength of nine different adhesive or self-adhesive luting composites as well as their corresponding adhesive system with lithium disilicate. To do this, they used three different pretreatment methods. In addition to the classic hydrofluoric acid pretreatment (20 seconds at a concentration of 4.5 percent) and leaving out pretreatment with hydrofluoric acid, an exclusive pretreatment with a two-component universal adhesive (UNIVERSAL BOND II, TOKUYAMA DENTAL) was also employed.

The scientists then determined the shear bond strength values between the luting composite and lithium disilicate at three different times:



after aging in distilled water heated to 37 degrees Celsius for one day, after 5,000 thermal cycles, and after 20,000 thermal cycles. This was intended to simulate two years of wearing the restoration.

Two-bottle adhesives have the advantage

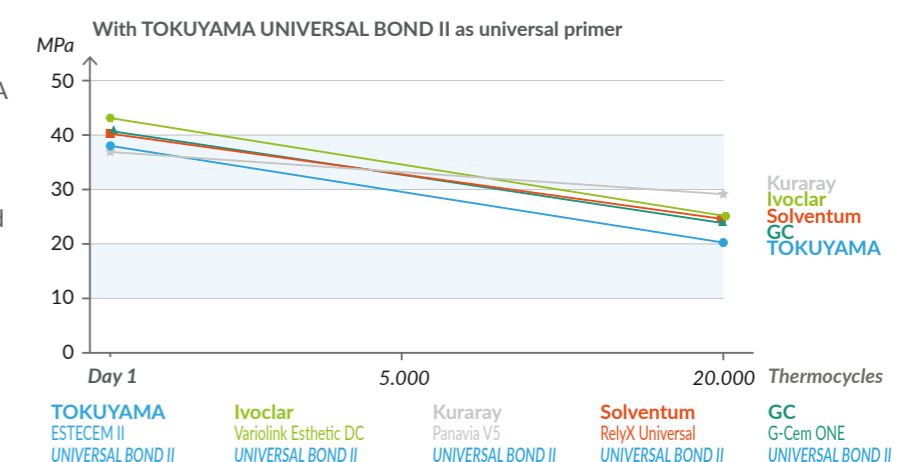
As a null hypothesis, the researchers had assumed that the bond strength would decrease significantly over time after pretreatment with a single-bottle adhesive only. The measurements confirm this assumption: if hydrofluoric acid is not used for pretreatment and only the adhesive system of the luting composite is used, the adhesion values approached the zero line in almost

all cases at 20,000 thermal cycles. The only exceptions were the luting composites ESTECCEM II (TOKUYAMA DENTAL) and Super-Bond Universal (Sun Medical) with their respective adhesive systems. Even after 20,000 thermal cycles, they still demonstrated adhesion values in excess of 20 MPa. Both systems have one thing in common: they are two-bottle adhesives. The reason for this significant difference, according to the research group, is that, in contrast to one-bottle adhesives, the silane adhesion promoting agent in two-component adhesives can only break down once both components have been mixed.

Wide compatibility & future potential

Yet another finding: when examining the third pretreatment mode, which involved exclusive pretreatment with the universal adhesive UNIVERSAL BOND II (TOKUYAMA DENTAL), the scientists were able to determine good adhesion values in combination with luting composites from other manufacturers. After 20,000 thermocycles, the adhesion values were higher than those that could be achieved without hydrofluoric acid pretreatment with the respective recommended adhesive system.

These results show that UNIVERSAL BOND II is highly compatible when used with other common luting composites – also including self-adhesive systems. From the scientists' point of view, the universal adhesive qualifies as a viable alternative to pretreatment with hydrofluoric acid based on these results.



Furthermore, the spectrum of applications for the product could possibly be extended in the future, even beyond the manufacturer's recommendations, and the universal adhesive could be used quite generally as a pretreatment agent for bonding lithium disilicate and luting composites.

Conclusion for the dental practice

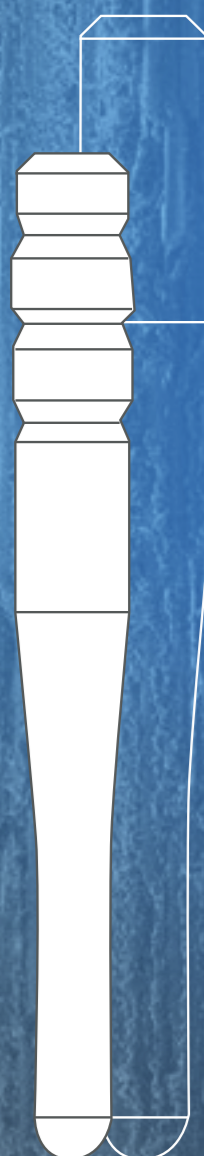
If adhesive bonding of lithium disilicate restorations is performed without pretreatment with hydrofluoric acid, a reliable and durable bond can nonetheless be achieved with two-component adhesive systems. A current study has confirmed that the universal adhesive UNIVERSAL BOND II (TOKUYAMA DENTAL) is highly compatible when used with various adhesive and self-adhesive luting composites.

References/sources

- ¹ Hajto J. Zeitgemäße Vollkeramik. Materialeigenschaft und klinische Anwendung. CME-Beilage in: Der Freie Zahnarzt 11/2012.
- ² Manhart J. Intraorale Reparatur von Keramikeinlagefüllungen. ZMK, 2019. 35(3): S. 94-103.
- ³ Irie, M.; Okada, M.; Maruo, Y.; Nishigawa, G.; Matsumoto, T. Long-Term Bonding Performance of One-Bottle vs. Two-Bottle Bonding Agents to Lithium Disilicate Ceramics. Polymers 2024, 16, 2266. <https://doi.org/10.3390/polym16162266>.

POSTS

Root posts made of quartz fibres form a solid foundation for prosthetic restorations.



Keyfacts Root pins

Anatomical shape

The optimised design supports the main models of Ni-Ti instruments, protecting the dentine within the root canal.

Excellent load-bearing capacity and flexibility

The dentine-like flexural properties guarantee a long durability of the restoration. The risk of root fractures is thus minimised.

Translucency

The extremely high translucency of the quartz fibre post ensures successful light-curing of the luting cement, e.g. ESTECER II PLUS, in the apical area.

Radiopacity

The ideal radiopacity enables accurate diagnosis in the future.

Calibrated drill

The TokuDrill for removing dentine has a slightly larger diameter (+0.05 mm) than the quartz fibre posts to ensure an even, thin layer of cement.

Colour coding

For quick size determination, the quartz fibre posts have colour-coded heads.

High biocompatibility

The quartz fibres minimise the risk of allergies and thus contribute to patient safety.

Verifier

The autoclavable carbon pin is used to check and determine the length and dimensions of the root canal.

TOKUPOST

Not just a glass fibre post – quartz fibres provide multiple benefits.

Translucency

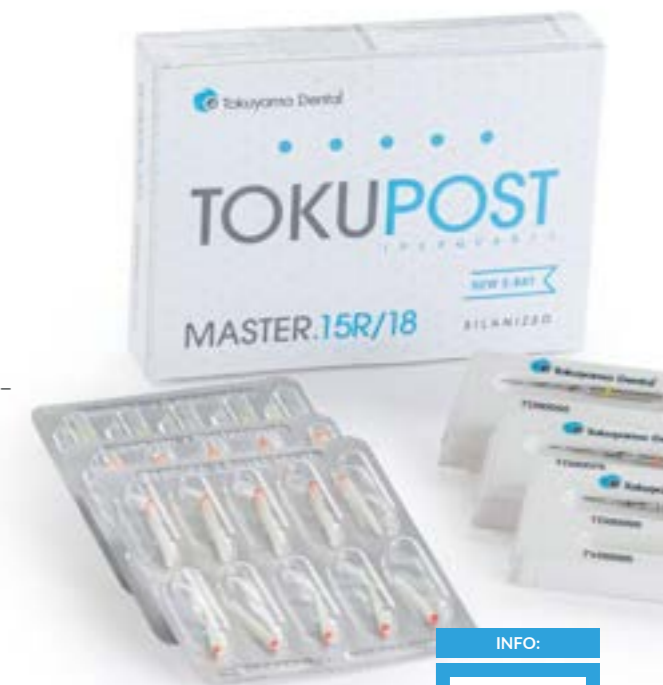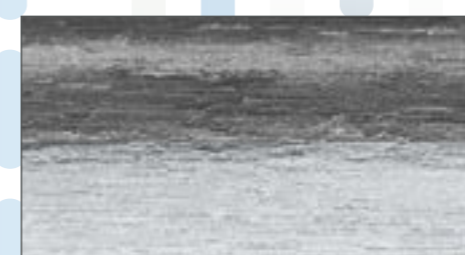

Crystal clear quartz fibres offer better transmission of polymerisation light – safe curing up to the apical area.

Unidirectional

The quartz fibres are arranged unidirectionally for dentine-like resilience. The dense bundling also provides stability.

Surface

During production, the posts are roughened with brushes to obtain a micro-retentive surface – for better adhesion.



INFO:

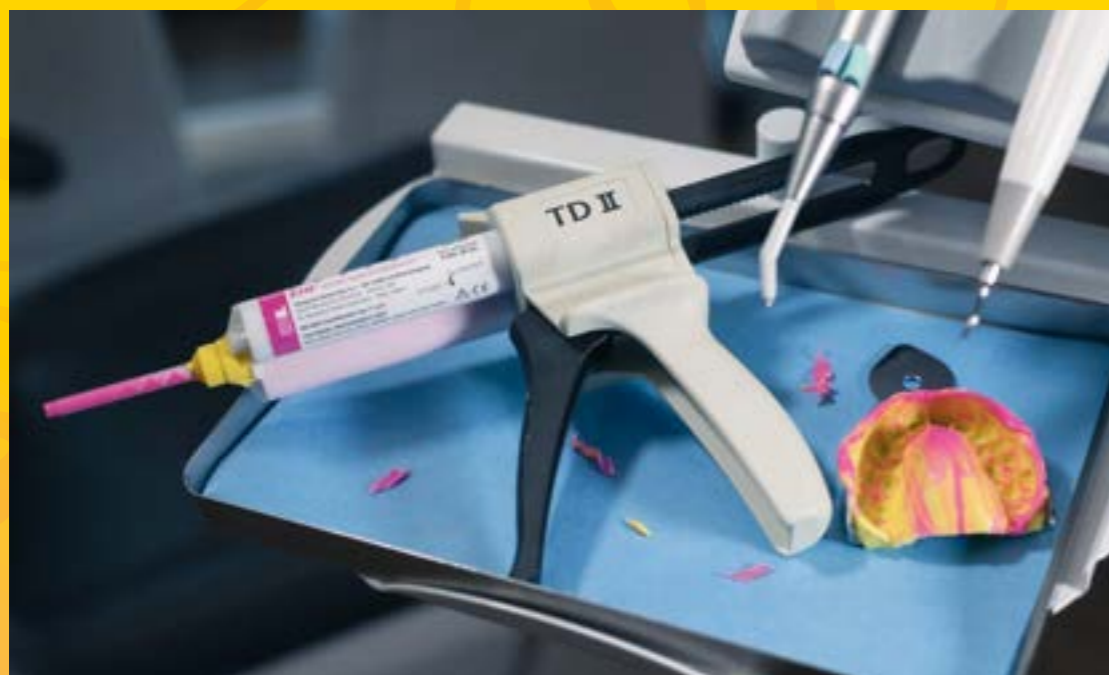

Customers also bought this additional product:
UNIVERSAL BOND II

More at BONDINGS >> UNIVERSAL BOND II

IMPRESSION MATERIALS

One system – all possibilities

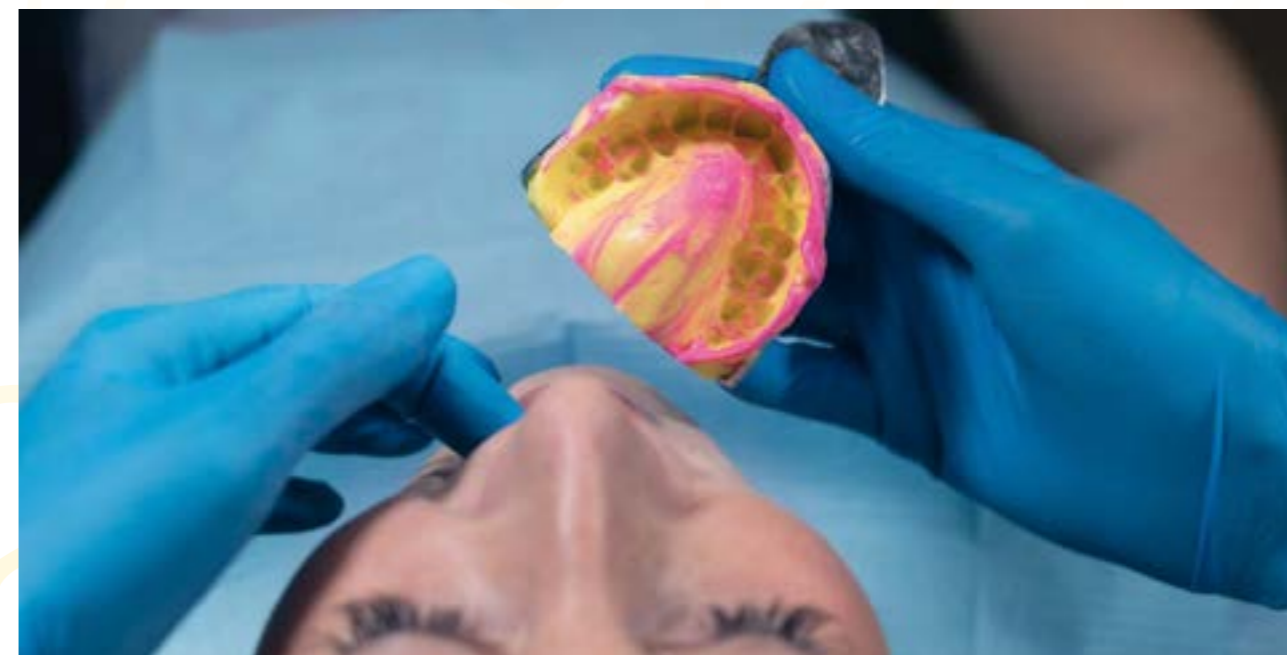


Despite the rapid development of digital impression systems, traditional impression taking still has its justification and is used in a large number of practices.

ESTESIL H₂TOP™ has various base materials and correction compounds to suit all impression techniques. Based on the type of prosthesis to be fabricated, the practitioner will prepare the tooth accordingly.

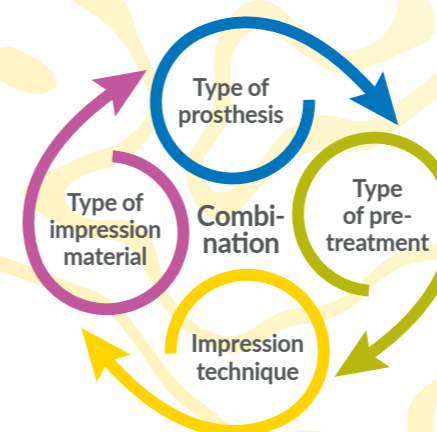


- > Detailed impressions even under difficult conditions
- > High resistance with simultaneous dimensional stability
- > The right material for every impression technique



The impression material to be chosen determines the optimal impression technique for the respective application. No matter which restoration or which technique is to be used: ESTESIL H₂TOP™ offers you all possibilities!

By combining with other technologies from TOKUYAMA, Polyvinylsiloxane has been created that has an extremely wettable surface due to the addition of surface-active, hydrophilic fillers. The precise reproduction of detail enables the practitioner to achieve a TOP result. It is the reproduction of details beyond the visible range that makes the difference.



„TOKUYAMA ESTESIL
is an excellent impression
material for daily use.“

Dr. Andrea Fabianelli,
Siena (ITA)



ESTESIL H₂TOP™

A-silicone for highest demands and accuracy.

All techniques

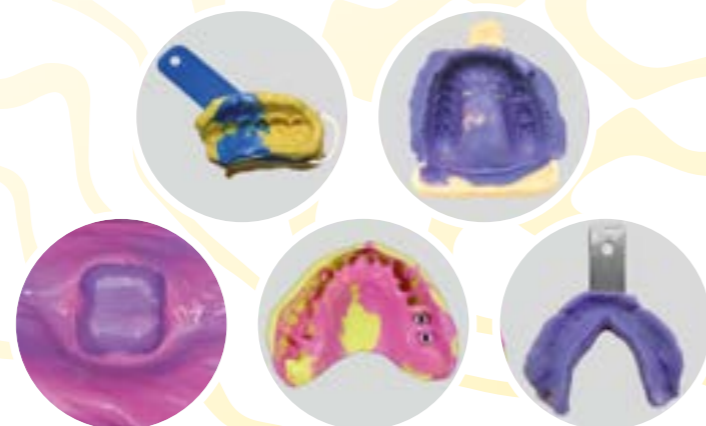The right impression material at hand for every situation – numerous combination possibilities.

Surface active

A special platinum catalyst ensures excellent surface wettability. Strong even in humid environments.

Tear-resistant

Even with hard-to-remove impressions, the details are preserved.



Dual-Arch technique, monophasic impression, Putty-wash-technique, double mixing technique or two phase impression, everything is possible with ESTESIL H₂TOP.



Customers also bought this additional product:
Dispenser (lightweight) ESTESIL

More at >> www.tokuyama-dental.eu

ESTESIL H₂TOP™ FAST

True-to-detail impression without a long wait – the fast way to the goal.

Fast

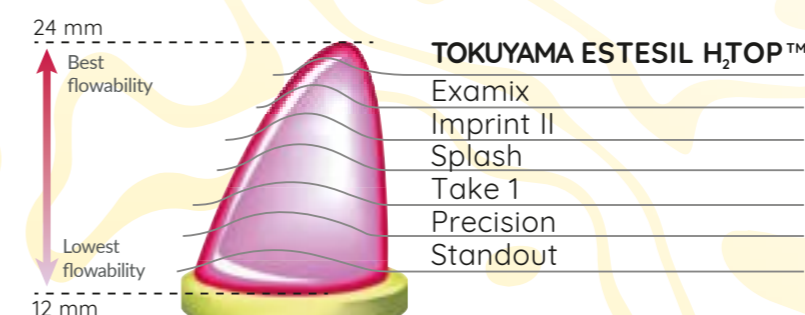
The faster setting reaction ensures speedy work without long waiting times.

Visibility

Colour-coordinated base and correction compounds ensure optimum visibility of the details.

Resilience

Excellent resilience ensures that the impression is and remains dimensionally stable.



Customers also bought this additional product:
SYMPRESS II mixing machine

More at >> www.tokuyama-dental.eu

DENTINE SEALANT

The double block – a protective shield for hypersensitive dentine.

Sealing the tubules with SHIELD FORCE PLUS



Dentine hypersensitivity is a pain that has been known for a very long time and is one of the most common types of pain in the dental practice. Studies show that about 15~20% of all patients suffer from dentine hypersensitivity.

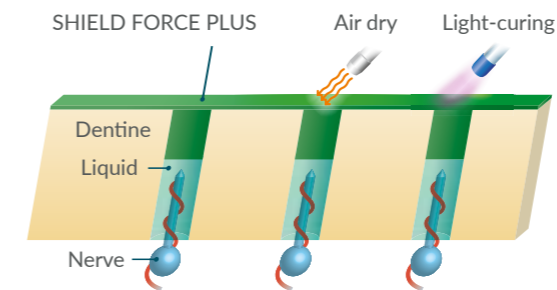
This pain is triggered by fluid movements of the dentine liquor in the open tubules, which irritate the underlying nerve.

In particular, the increasing wear of the teeth through e.g. abrasion or erosion exposes the dentinal tubules. A reliable dentine sealant can provide relief here.



- Quick and easy handling
- Excellent sealing effect
- Effective & resistant protective coating

SHIELD FORCE PLUS



Fast pain relief

The reaction of the 3D-SR-Monomer provides relief in seconds.
Block 1 – Closure of the tubules.

Permanent pain relief


The resulting protective layer on the tooth surface is light-cured.
Block 2 – Provides sealing and effective protection.

Handling


Extremely easy to use. No rinsing or massaging.
Simply apply, leave on for 10 seconds, air blow and light cure. Done!

Thermal cycle test (10,000 cycles) at 4 °C–60 °C **

The sealing layer of SHIELD FORCE PLUS remains intact after the thermal cycle test.



Hypersensitive dentine model




After application of SHIELD FORCE PLUS



After the thermal cycle test (10,000 x)


Sealing layer of the Gluma® Desensitizer (Kulzer) washes out during the thermal cycle test.



Hypersensitive dentine model



After the application of Gluma® Desensitizer



After thermal cycle test

* Not an own trademark of TOKUYAMA Dental Corp.

** Source: TOKUYAMA DENTAL R&D



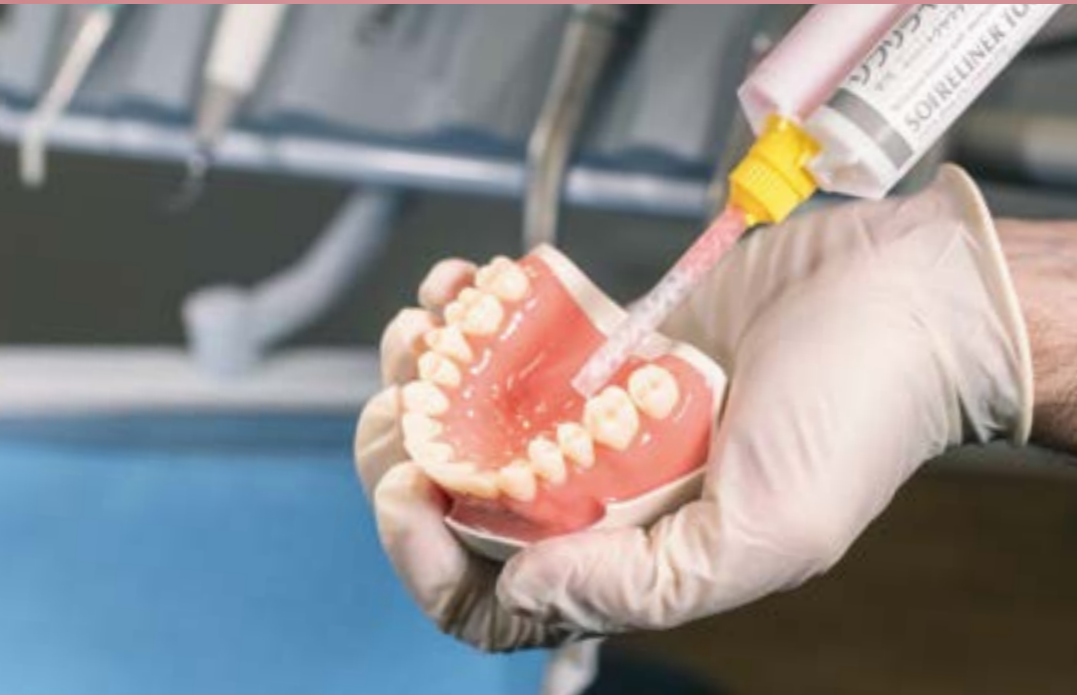„The clinical application is extremely simple and very user-friendly.“

Dr. med. dent.
Markus Th. Firla
Osnabrück (GER)

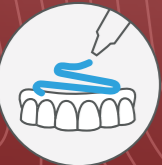

RELINING MATERIAL

Denture relining material for long-lasting wearing comfort with maximum reliability



Over the years, dentures can lose their hold and the once good fit. The conditions of the jaw or the oral cavity change. TOKUYAMA DENTAL relining materials promise a quick remedy in such cases, without requiring a great deal of effort. The materials are suitable for both the dentist and the dental technician. Different Shore hardnesses ensure that the appropriate material is available for every treatment case. Hard relining materials provide the usual support, while soft relining materials provide comfort when the prosthesis is pressing or pain needs to be relieved. No matter what level of support is required, both materials promise a long-term restoration.



- Can be used chairside or in the laboratory
- Hard or soft relining
- Long durability and reliability

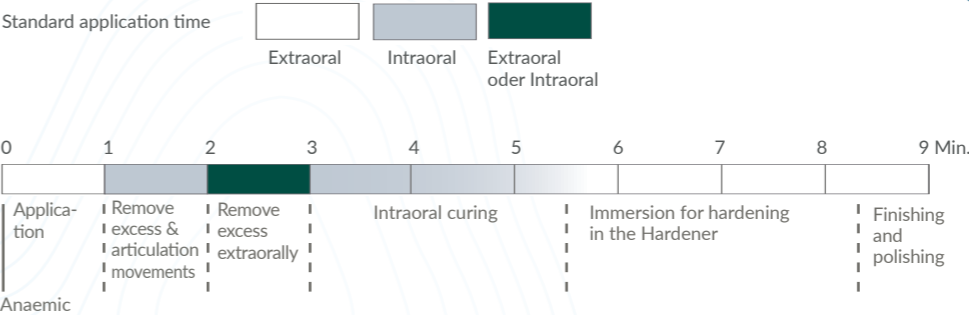
REBASE II FAST

The classic – tried and tested for years and recognised for hard relinings.

Time and cost saving
The material can also be used chairside.
No waiting time for the patient, no laboratory costs for the dentist.

Pleasant
Low temperature development, no unpleasant taste or smell and MMA-free.

Permanent
A special hardener removes the top oxygen inhibition layer and thus causes complete curing. No breeding ground for bacteria or bad odours – for long-lasting use.



SOFRELINER TOUGH M

Permanent soft relining – long-lasting wearing comfort for up to 2 years.

Time and cost saving

The material can also be used chairside.
No waiting time for the patient, no laboratory costs for the dentist.

Permanent

No peeling or tearing of the relining – permanent hold.
Likewise lasting comfort without any loss of material stability.

Safe mouthfeel

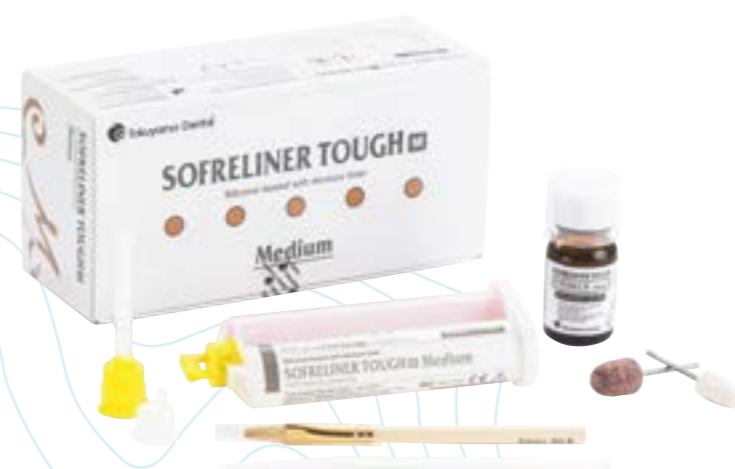Smooth surface offers little surface for plaque – no bad odours.

High tear strength



SOFRELINER TOUGH

Comparison product



Customers also bought this additional product:
Dispenser II for SOFRELINER

More at >> www.tokuyama-dental.eu

SOFRELINER TOUGH S

When even more wearing comfort is needed – the extra-soft version.

Extra-soft

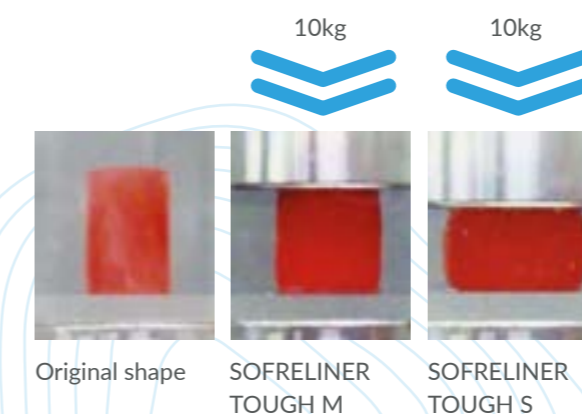
Excellent for interim care (max. 1 year),
e.g. for wound healing after operations.

Excellent

Awarded several times by Dental Advisor
as the best soft relining material.

Stable

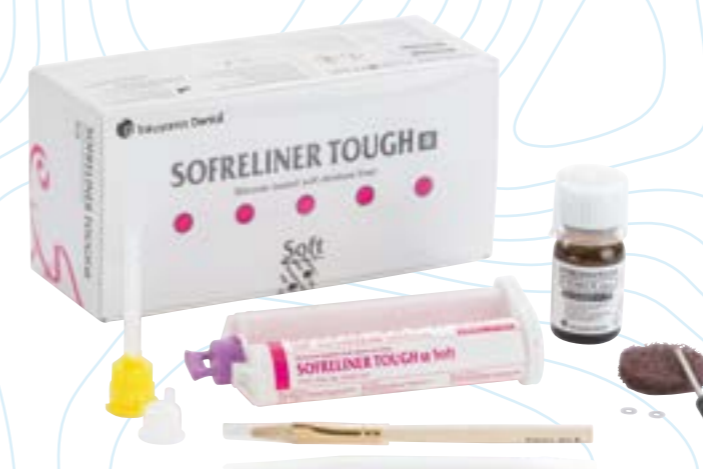High resistance to discolouration or wear.



Original shape

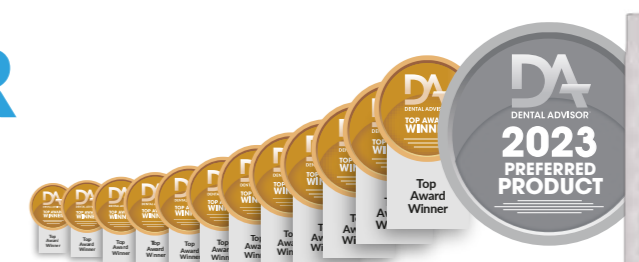SOFRELINER TOUGH M

SOFRELINER TOUGH S



Customers also bought this additional product:
SILICONE REMOVER

More at >> www.tokuyama-dental.eu



TANNHJÓL-MÁNAFOSS ehf.
Iceland

TS DENTAL
Sweden

THE DISTRIBUTION AREA

Our dealer network – Selected partners
for service, quality and advice!

Our official exclusive partners at a glance

DE | KANIEDENTA GMBH & CO. KG.
www.kaniedenta.de

DK | ZENITH DENTAL APS
www.zenith-dental.dk

AT | LEIBETSEDER
DENTALWARENHANDEL GMBH & CO. KG
www.dental-leibetseder.at

IS | TANNHJÓL-MÁNAFOSS ehf.
www.manafoss.is

CH/LI | MEDIREL SA
www.medirel.com

NO | LIC SCADENTA AS
www.licscadenta.no

PL | MARRODENT SP. Z O. O.
www.marrodent.pl

FI | Dental Service Nick OY
www.dsnick.fi

UK | TRYCARE LTD
www.trycare.co.uk

EE | MEDSHOP OÜ
www.medshop.ee

IR | KARMA SALES & SERVICE LTD
www.karmadental.com

LT | TIK UNIDENTAS UAB
www.unidentas.lt

NL | HOFMEESTER DENTAL BV
www.hofmeester.nl

LV | ZRK VLATA SIA
www.vlata.lv

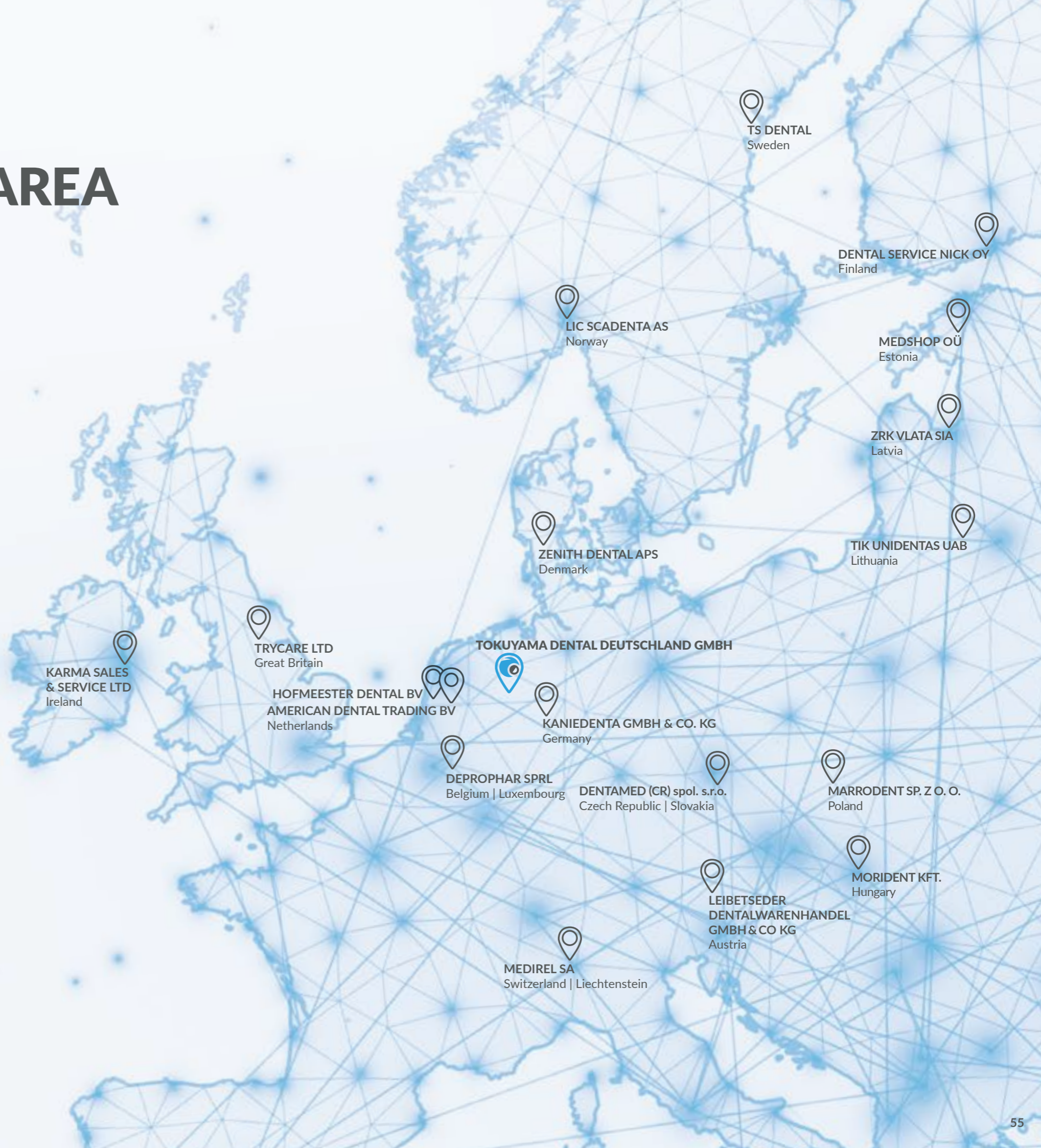
AMERICAN DENTAL TRADING BV
www.adt.nl

CZ/SK | DENTAMED (CR) spol. s.r.o.
www.dentamed.cz

BE/LU | DEPROPHAR SPRL
www.deprophar.com

HU | MORIDENT KFT.
www.morident.hu

SE | TS DENTAL
www.tsdental.se



DENTAL SERVICE NICK OY
Finland

LIC SCADENTA AS
Norway

MEDSHOP OÜ
Estonia

ZRK VLATA SIA
Latvia

TIK UNIDENTAS UAB
Lithuania

ZENITH DENTAL APS
Denmark

TRYCARE LTD
Great Britain

TOKUYAMA DENTAL DEUTSCHLAND GMBH

HOFMEESTER DENTAL BV
AMERICAN DENTAL TRADING BV
Netherlands

KANIEDENTA GMBH & CO. KG
Germany

DEPROPHAR SPRL
Belgium | Luxembourg

DENTAMED (CR) spol. s.r.o.
Czech Republic | Slovakia

MARRODENT SP. Z O. O.
Poland

LEIBETSEDER
DENTALWARENHANDEL
GMBH & CO KG
Austria

MORIDENT KFT.
Hungary

MEDIREL SA
Switzerland | Liechtenstein

TOKUYAMA Dental Deutschland GmbH

Sales: Fürstengrund 14 | 48629 Metelen
Phone: +49-2556-999910

Administration: Am Landwehrbach 5 | 48341 Altenberge
Phone: +49-2505-938513

E-Mail: info@tokuyama-dental.de

tokuyama-dental.eu



fb.com/TokuyamaDE



[instagram.com/
tokuyamadentalgermany](https://instagram.com/tokuyamadentalgermany)



[linkedin.com/company/
tokuyama-dental-germany](https://linkedin.com/company/tokuyama-dental-germany)



[youtube.com/
@Tokuyama-Germany](https://youtube.com/@Tokuyama-Germany)